Diagnostik

Fortbildung Autoimmunerkrankungen
Wien 29.11.2014

Wolfgang Buchinger

Institut für Schilddrüsendiagnostik und Nuklearmedizin, Gleisdorf

Schilddrüsenordination Graz

Schilddrüsenambulanz der Internen Abteilung

Krankenhaus der Barmherzigen Brüder Graz-Eggenberg

Untersuchungsmethoden

- Anamnese
- klinisch physikalische Untersuchung
- Sonographie
- Szintigraphie
- Schilddrüsenhormonbestimmung
- Schilddrüsenantikörperbestimmung
- Feinnadelpunktion
- Zusätzliche bildgebende Verfahren
- Zusätzliche Untersuchungen

Anamnese

- Lokale Beschwerdesymptomatik
- durch Funktionsstörung hervorgerufene Beschwerden
- Schilddrüsenerkrankungen in der Familie
  Immunthyreopathien
  Struma nodosa
  (medulläres) Schilddrüsenkarzinom
- vorangegangene Untersuchungen (wann? wo? was?)

Anamnese

- vorangegangene/aktuelle Therapie
  Schilddrüsenhormon
  Thyreostatika
  Operation
  Radiojodtherapie
- weitere Medikamentenanamnese
  Lithium
  Sedacorone
  Beta-Isodona
  PPI
  Blutgerinnung beeinflussende Medikation

Klinisch physikalische Untersuchung

- Palpation



Klinisch physikalische Untersuchung

- Palpation

A very high percentage of general surgery residents pursue fellowship training, which implies keen competition with other specialized surgical disciplines for outstanding fellowship candidates. With the fascinating and stimulating subject matter (admittedly, we are biased!), the ongoing commitment to the clinical, research, and educational aspects on the part of both staff and fellows, we believe that the future of endocrine surgical training is bright."

The Thyroid Nodule Clinic

Thyroid nodules are common, with palpable nodules found in 4% to 7% of the adult US population and solitary or multiple nodules found at much higher rates during ultrasonographic screening. "Most of these nodules—about 95%—are entirely benign," says Hossein Gharib, MD, of the Division of Endocrinology, Diabetes, Metabolism, and Nutrition at Mayo Clinic in Rochester, Minnesota. "However, identifying the occasional thyroid cancer requires careful evaluation of every nodule we find, using a combination of clinical assessment, neck palpation [Figure 1], ultrasound imaging [Figure 2], and, in many cases, analysis of a biopsy specimen [Figure 3]."

Hossein Gharib, MD, Bryan McIver, MB ChB, PhD, Diana S. Dean, MD, and Melanie L. Richards, MD

Sometimes, thyroid nodules are noticed by the patient or a family member or are discovered during a routine physical examination. They rarely cause symptoms, unless they are large enough to interfere with swallowing. Thyroid cancer can invade and damage the recurrent laryngeal nerve, causing hoarseness. Such invasion and damage are infrequent, however. "Most nodules are incidental discoveries," notes Diana S. Dean, MD, of the Division of Endocrinology, Diabetes, Metabolism, and Nutrition at Mayo Clinic in Rochester, Minnesota, "and now many more such nodules are discovered because of the increased use of imaging performed for other reasons, including carotid ultrasonography, neck or chest computed tomography, magnetic resonance imaging, and even positron emission tomography."

Figure 1. *Palpation of the thyroid gland.*

"Diagnosing a thyroid nodule accurately and promptly is important," says Melanie L. Richards, MD, of the Department of Surgery at Mayo Clinic in Rochester, Minnesota, "because early diagnosis improves the likelihood that a cancer can be discovered while still contained within the thyroid gland and amenable to surgery. Once soft tissue invasion has occurred or lymph nodes are extensively involved, the chance of surgical cure drops substantially and there is a much higher incidence of metastatic spread of these late-stage cancers."

Prompt diagnosis is also important for the patient because the finding of a nodule often raises fears about cancer and a delay to diagnosis fuels the concern and anxiety. "The most recent

Klinisch physikalische Untersuchung

- Anzeichen für Hyperthyreose
  feinschlägiger Tremor
  Tachykardie
  endokrine Orbitopathie
  warme feuchte Haut

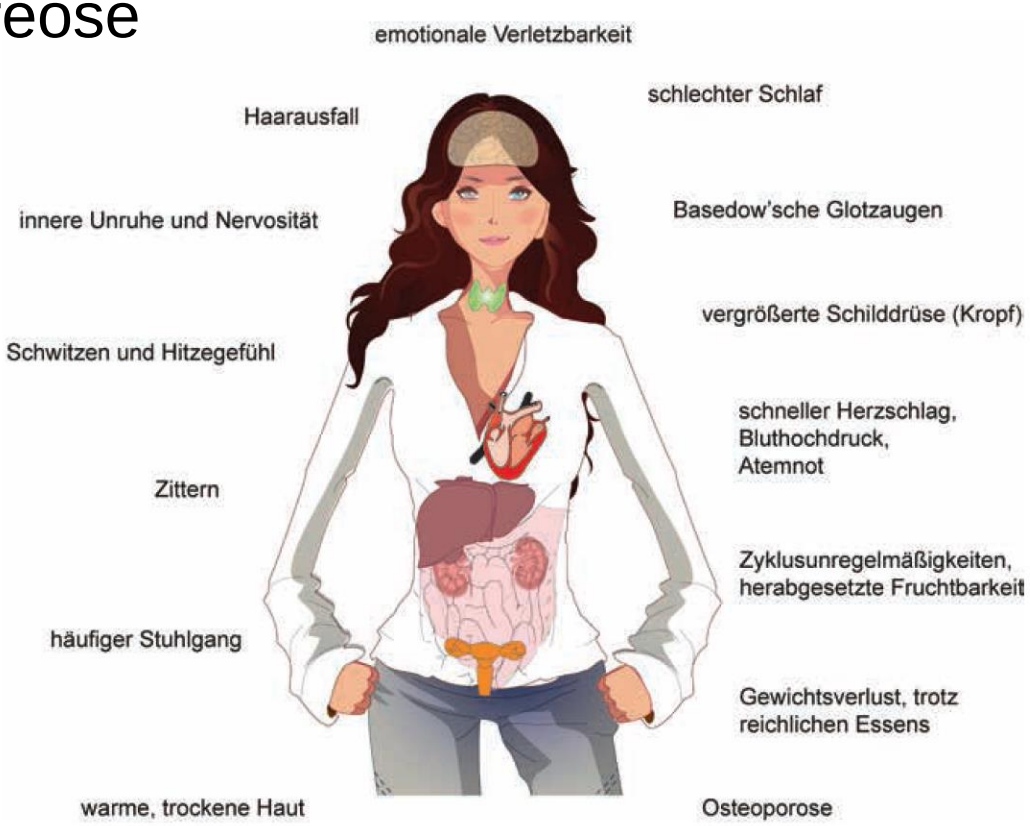

Aus:
Buchinger, Zettinig
Meine Schilddrüse und ich. 2014

Klinisch physikalische Untersuchung

- Anzeichen für Hypothyreose
  raue verlangsamte Stimme
  (Telefondiagnose)
  Kälteintoleranz
  Ödemneigung
  trockene raue Haut

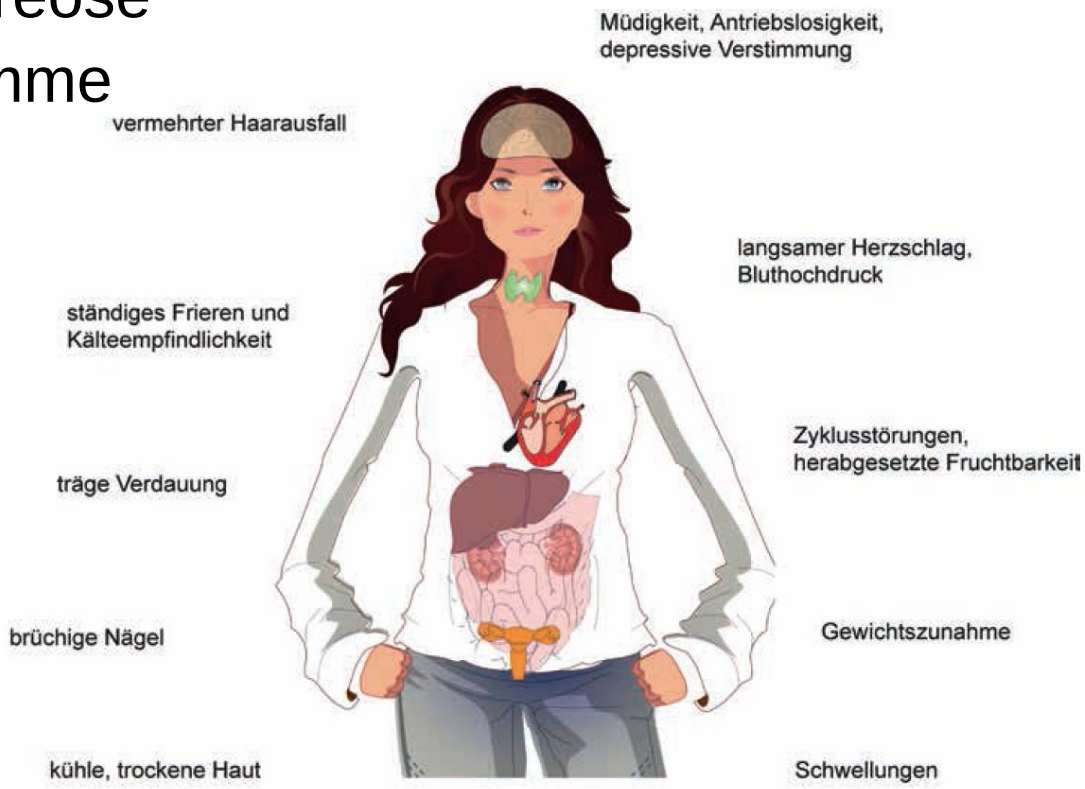

Aus:
Buchinger, Zettinig
Meine Schilddrüse und ich. 2014

Sonographie

Sonographie

Screening

Morphologische Information

Indikation

Hypo-, Aplasie, Ektopie

Morphologie: diffus, uni-, multinodös

Echogenität: hypo-, normo-, hyperechogen

Grösse: Volumetrie

Blutflussbestimmung

Hilfe bei diagnostischen und therapeutischen Punktionen

Schilddrüsenkarzinom in der Nachsorge

Beurteilung der regionären Lymphknoten

Sonographie

Normalbefund

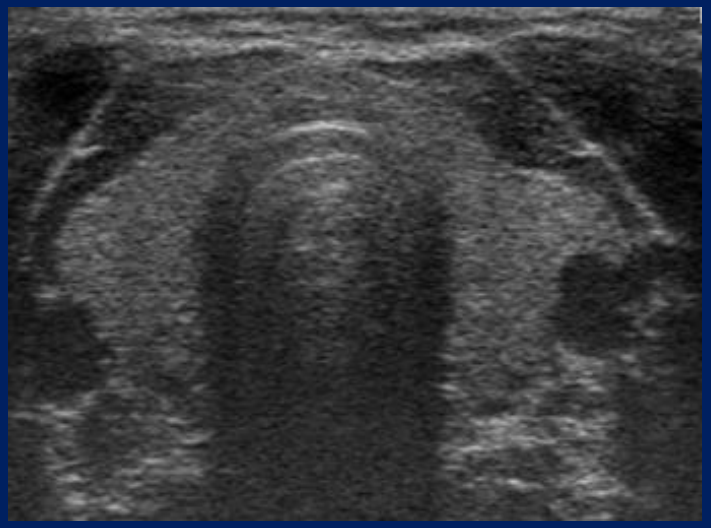

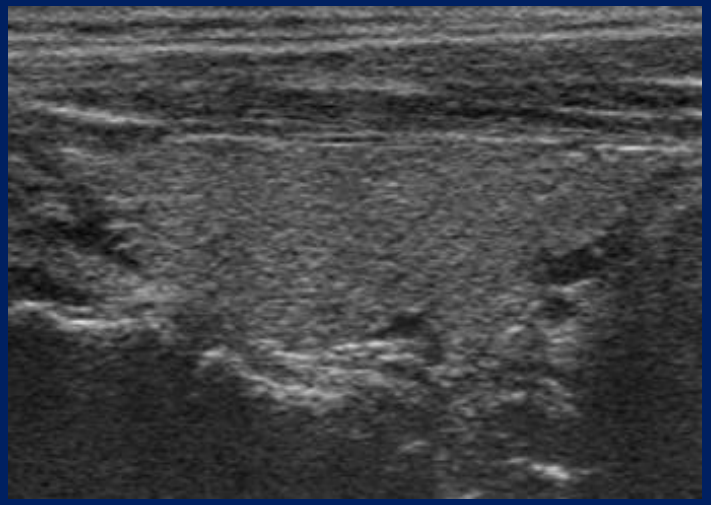

Sonographie

Normalbefund

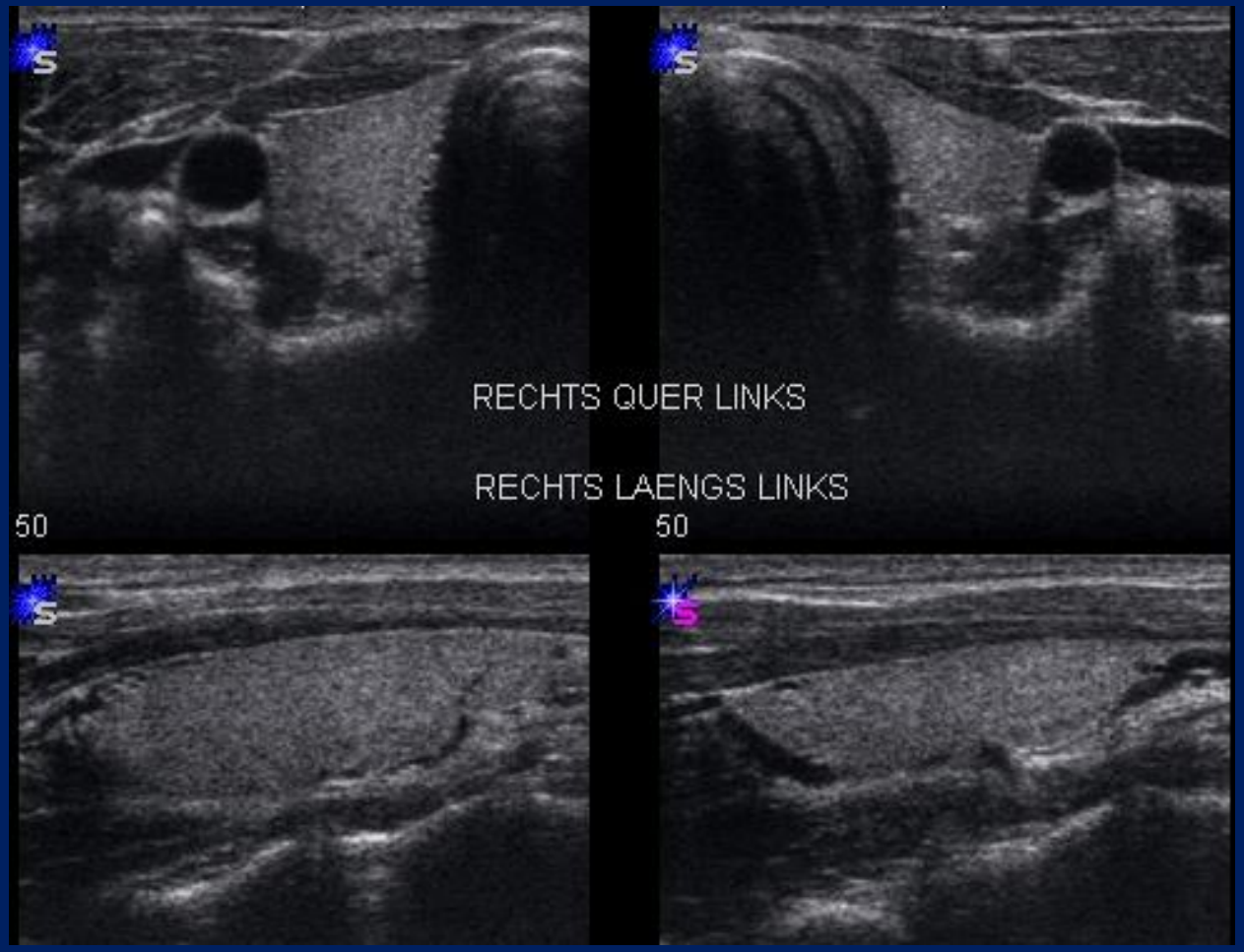

Hashimoto Thyreoiditis

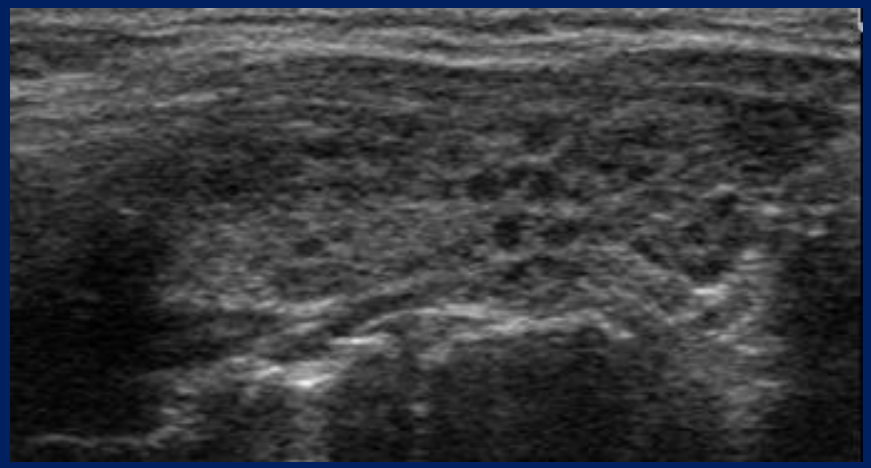

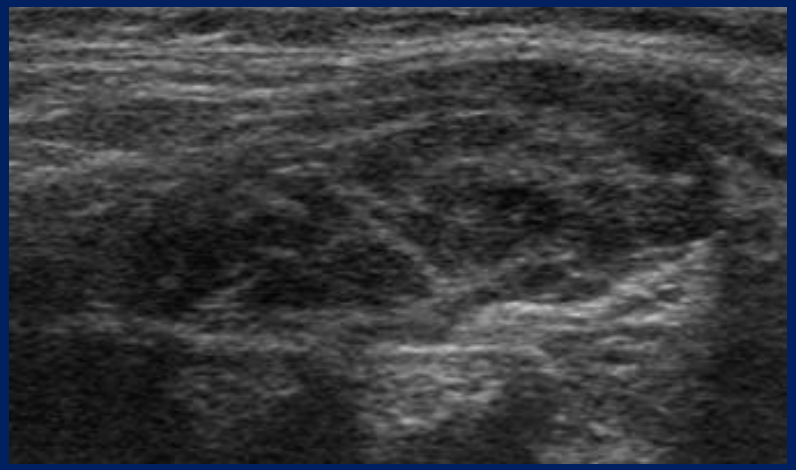

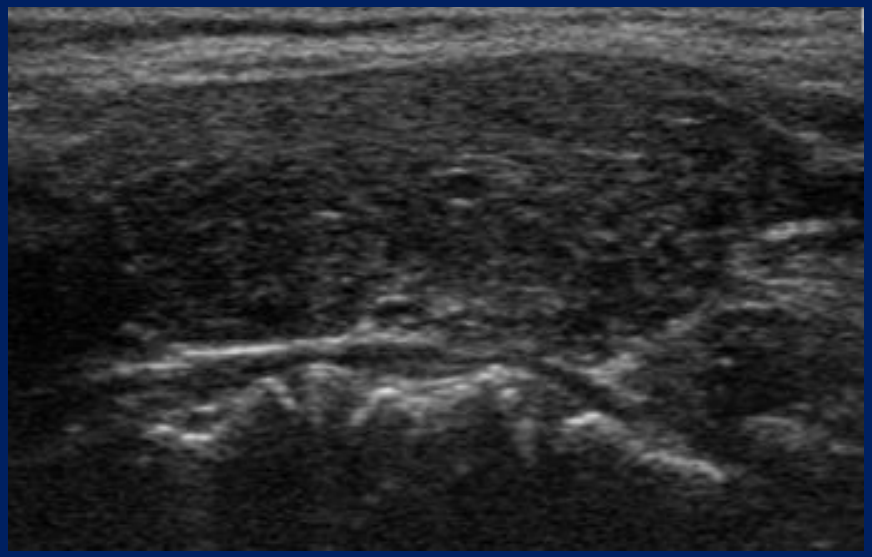

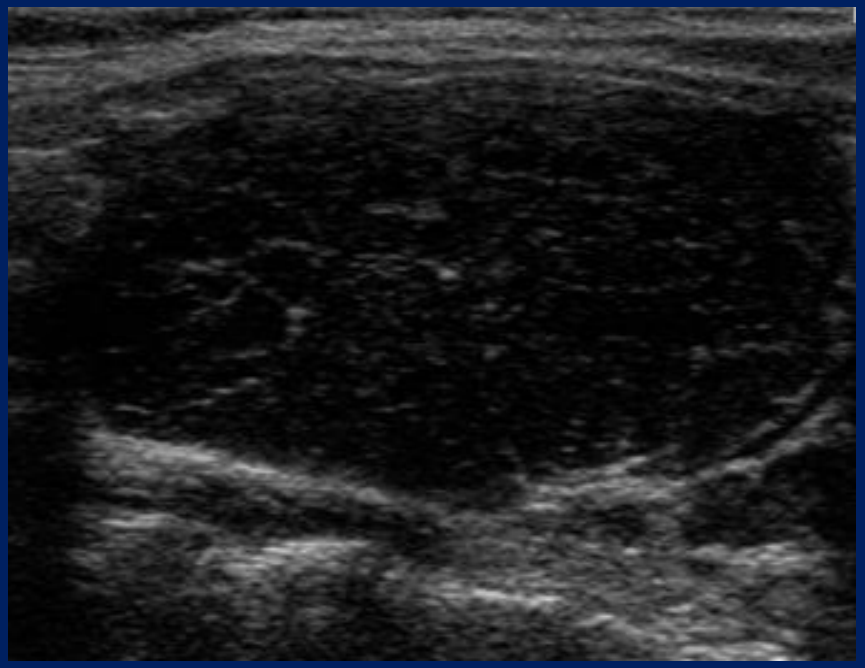

Immunhyperthyreose Typ Morbus Basedow

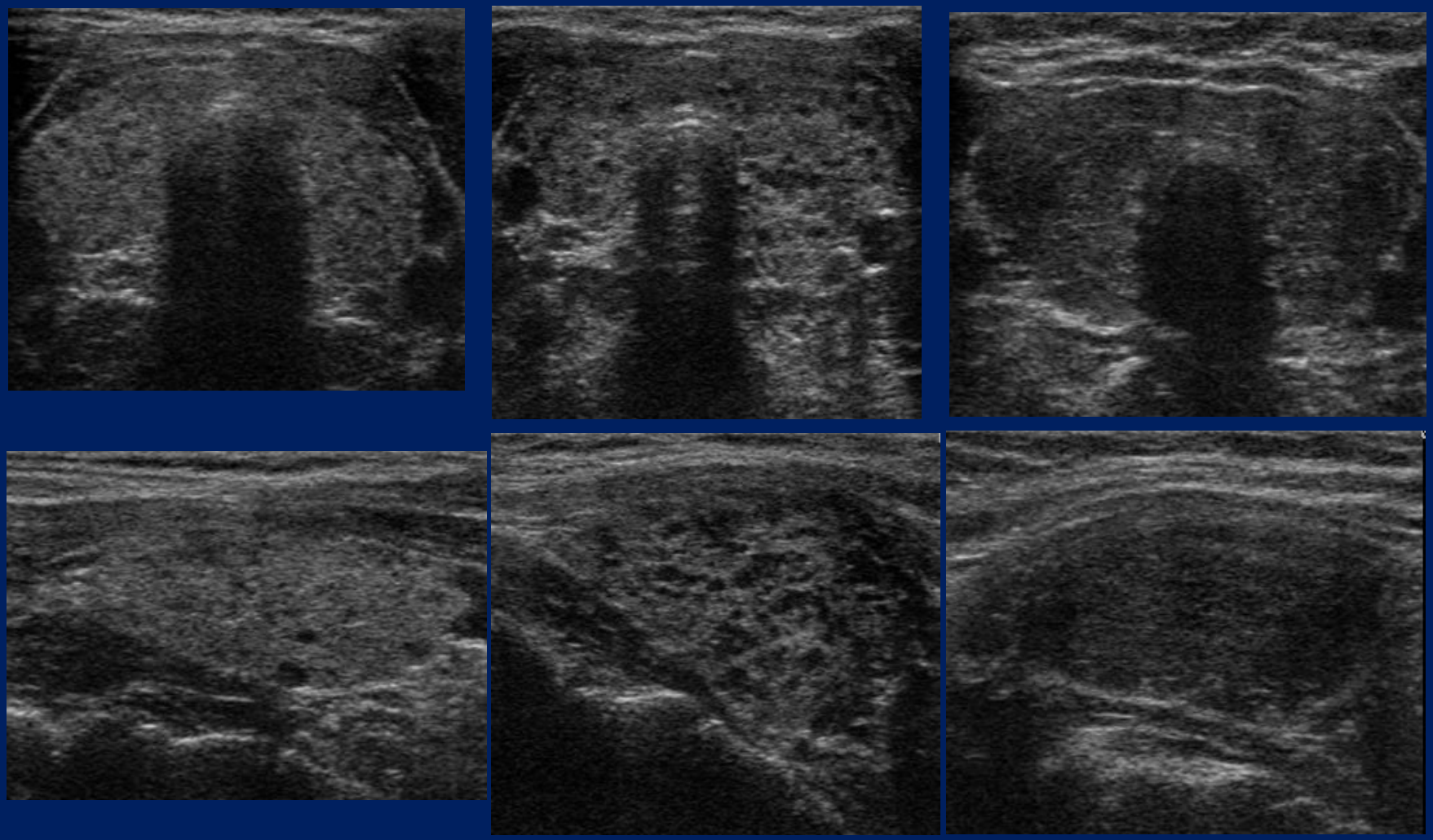

Doppler Hashimoto und Basedow

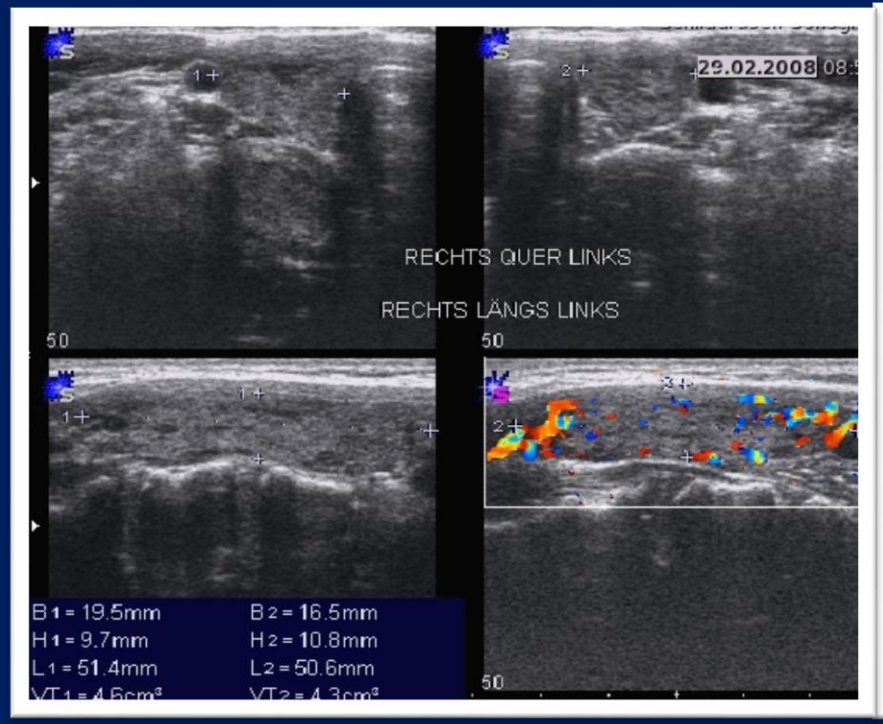

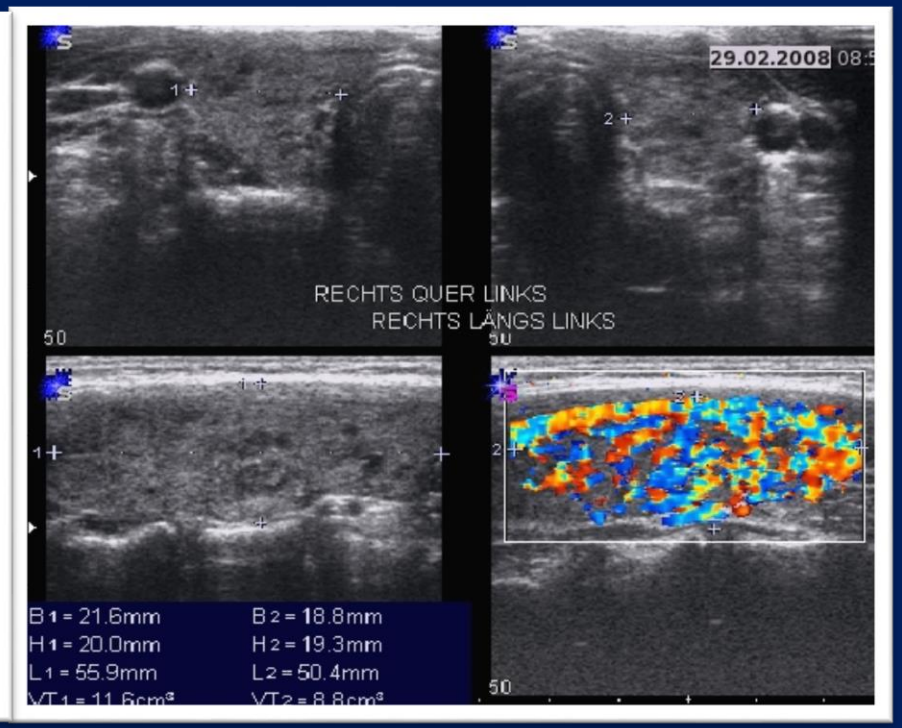

Szintigraphie

Szintigraphie

Funktionelle Information

Indikation

Struma nodosa

Funktionsstörungen

Schilddrüsenkarzinom in der Nachsorge

Dosimetrie vor Radiojodtherapie

Radionuklide

^{123}Jod	γ-Strahler	13h HWZ
^{99m}Technetium	γ-Strahler	6h HWZ
^{131}Jod	ß- und γ-Strahler	8d HWZ
^{201}Thallium	γ-Strahler	73,5h HWZ

Szintigraphie

Normalbefund

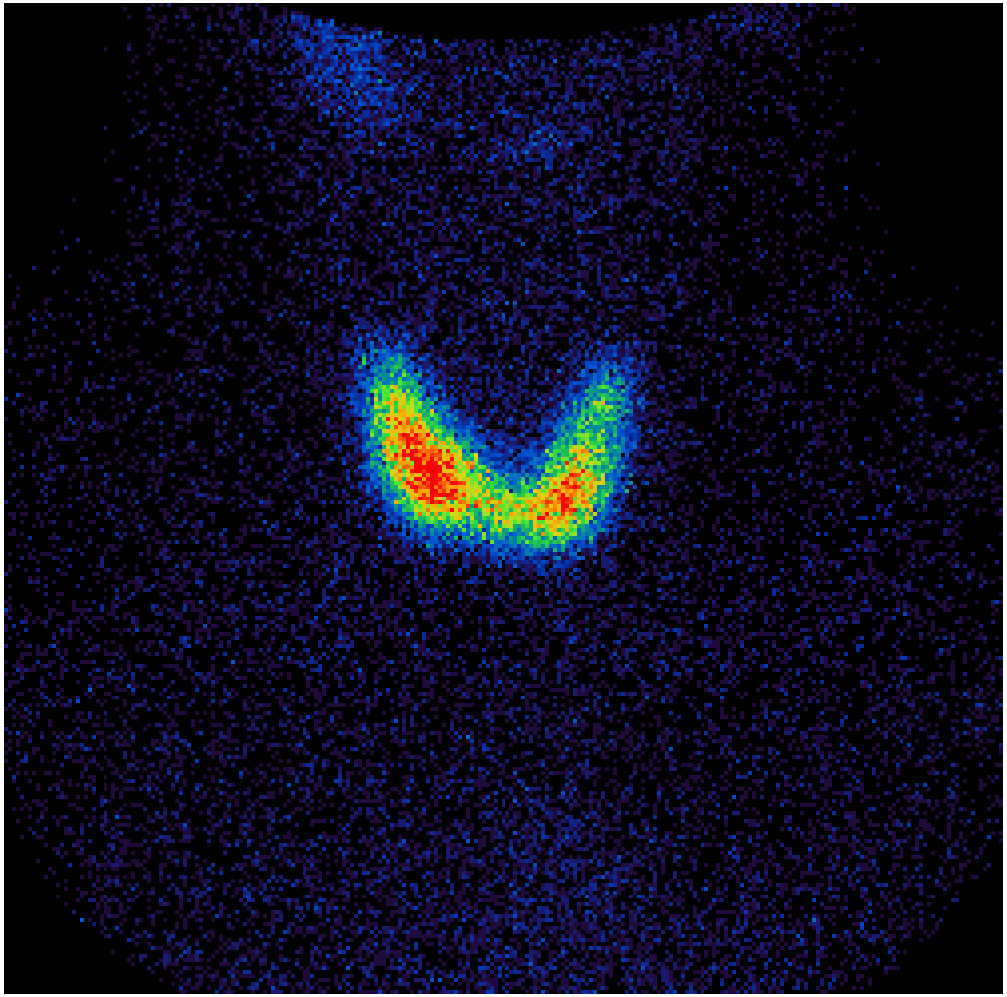

Szintigraphie

Normalbefund

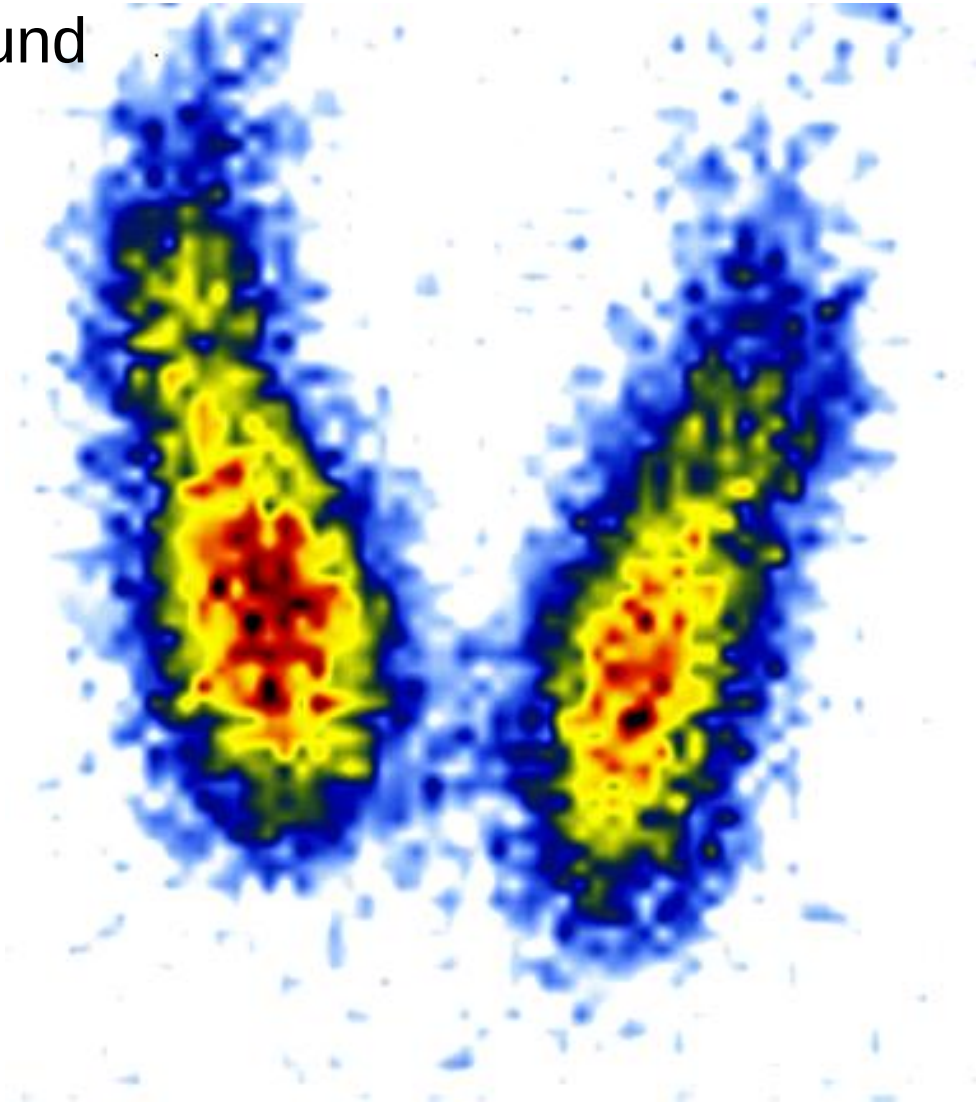

Szintigraphie

Normalbefund

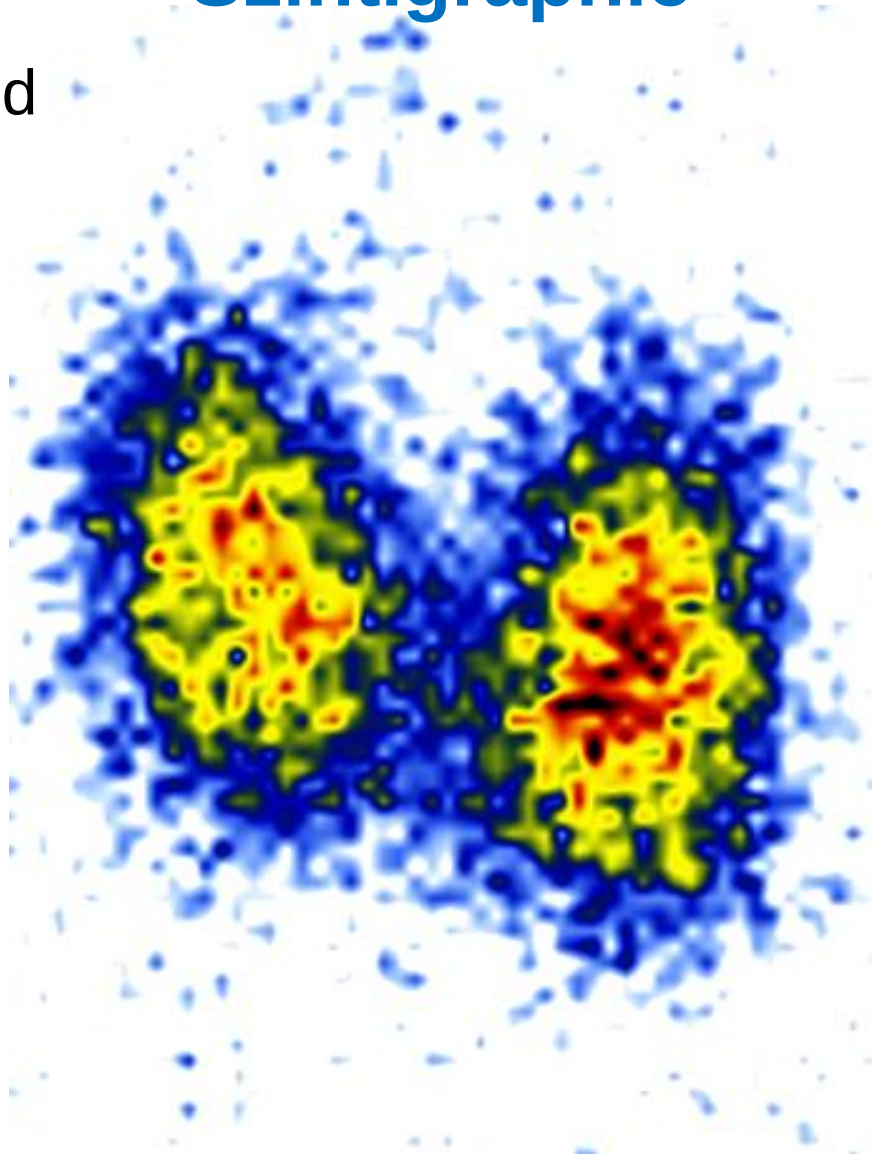

Szintigraphie

Hashimoto Thyreoiditis

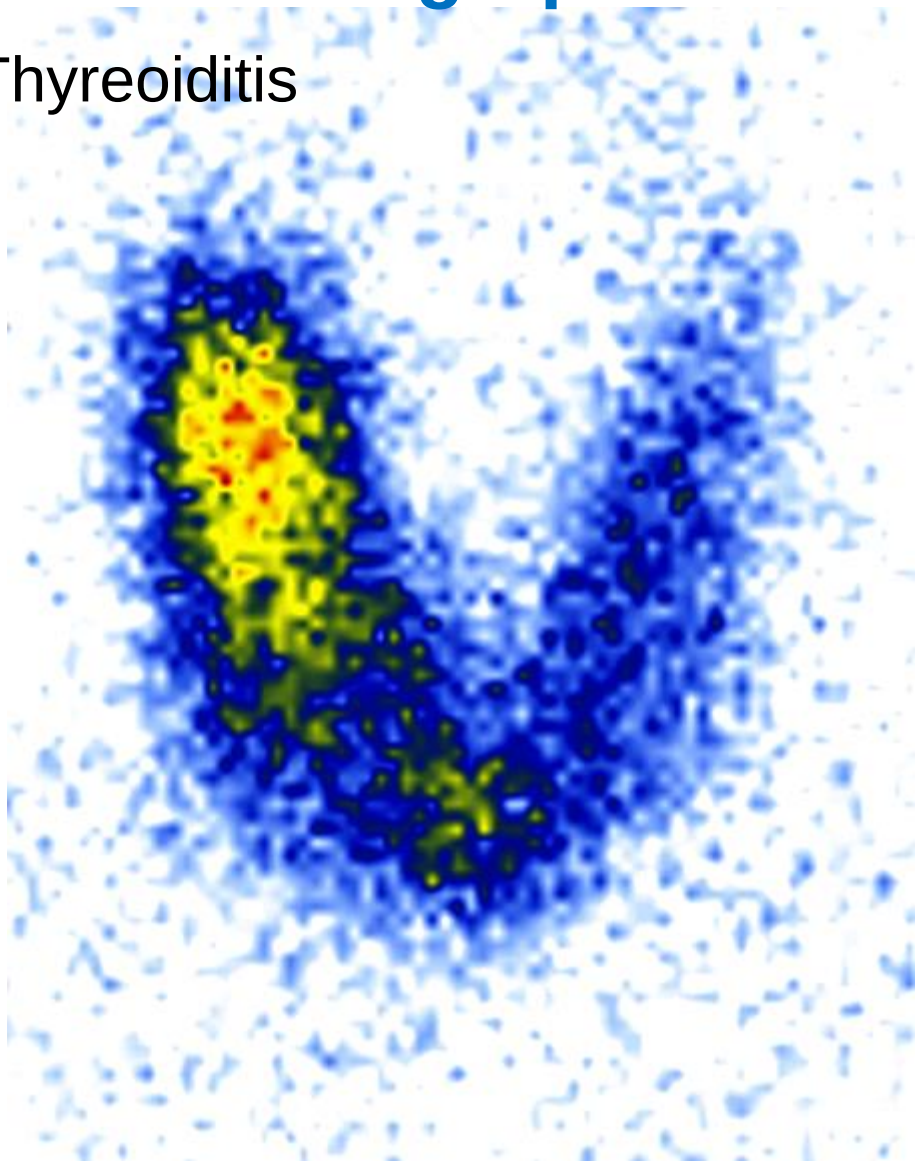

Szintigraphie

Immunhyperthyreose Typ Morbus Basedow

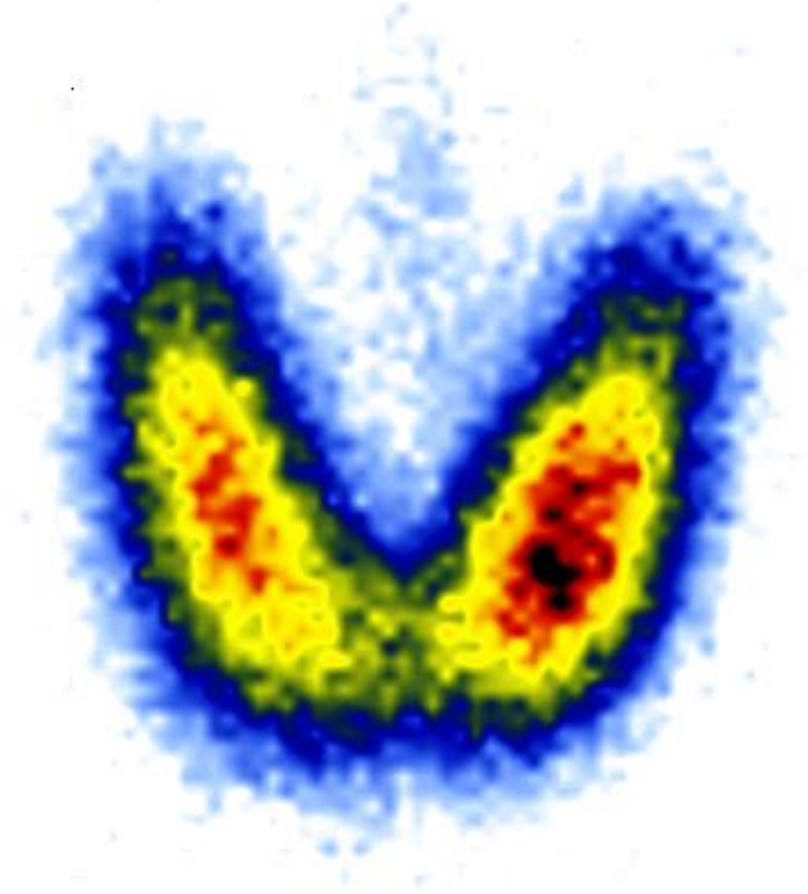

Szintigraphie

hyperthyreote Phase einer Hashimoto Thyreoiditis



Szintigraphie

Differentialdiagnose der Hyperthyreose

Zellzerfall



Mehrproduktion

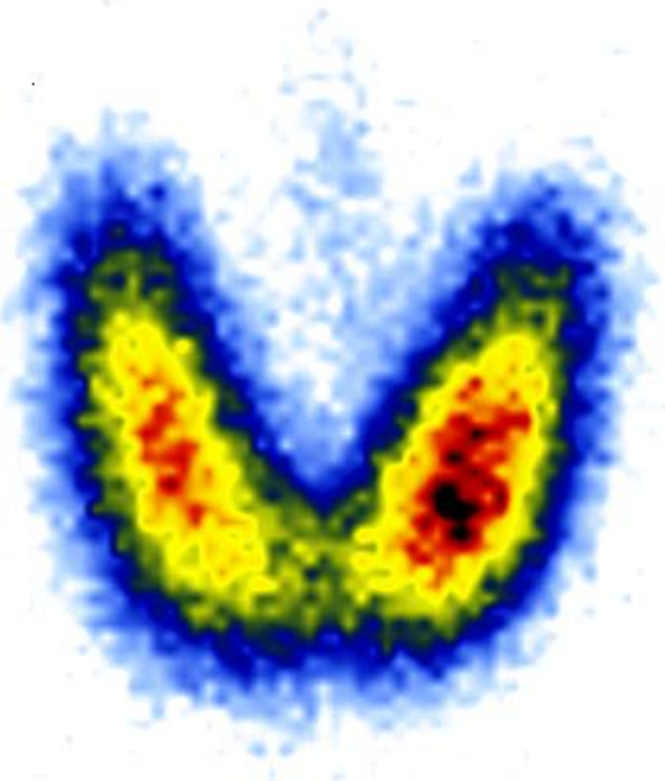

Hypothalamisch - hypophysär - thyreoidaler Regelkreis

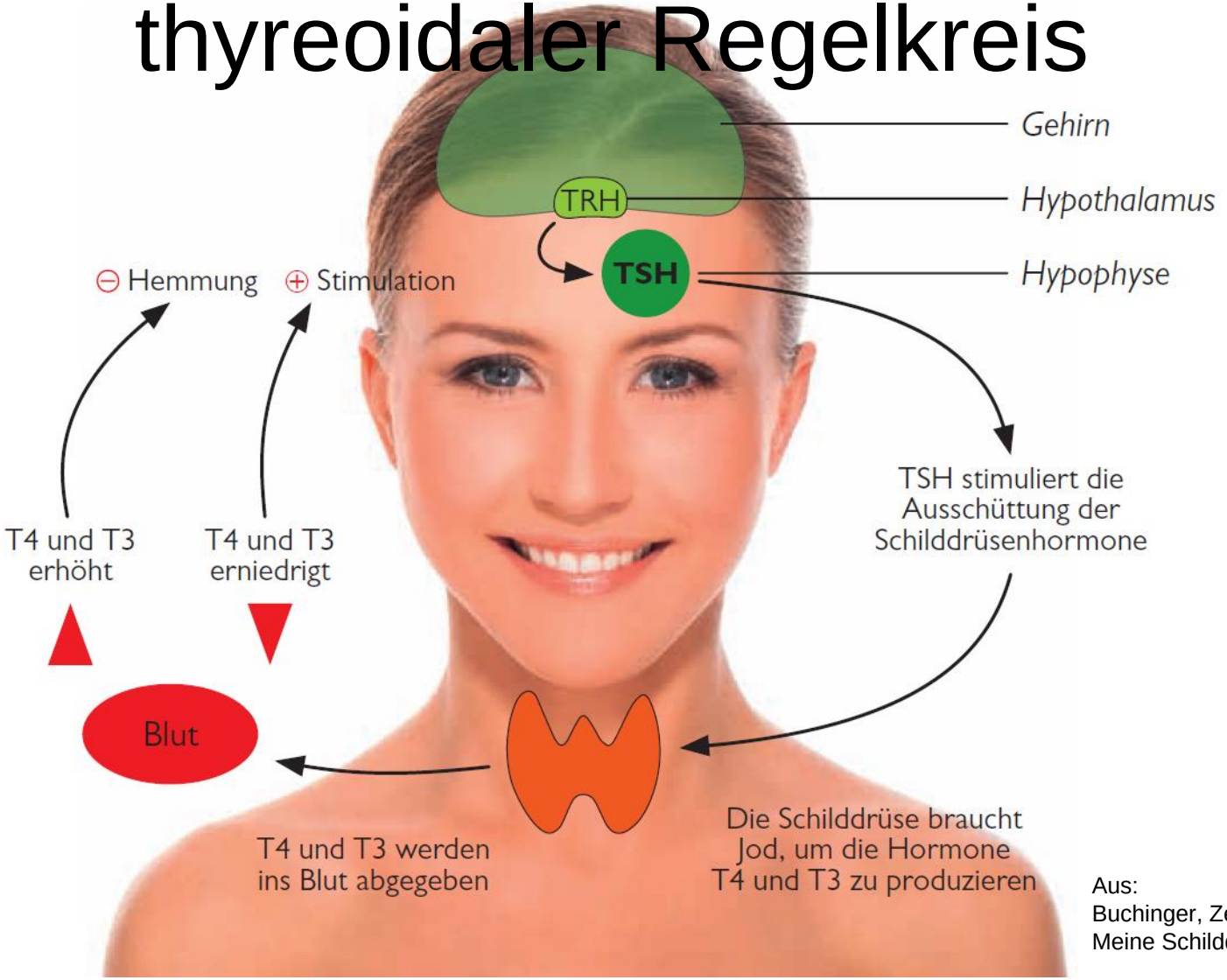

Aus:
Buchinger, Zettinig
Meine Schilddrüse und ich. 2014

Hormonbestimmung

- TSH-Bestimmung
- (nach TRH-Stimulation)
- freies T3, freies T4, Gesamt-T3, Gesamt-T4

- eindeutige Funktionszuordnung möglich

bTSH mU/L	ΔTSH mU/L	FT3	FT4	Funktion
0.28-4.2	*0*	↔	↔	*Euthyreose*

bTSH	ΔTSH	FT3	FT4	Funktion
mU/L	mU/L			
<0.1	0	↑	↔ / ↑	manifeste Hyperthyrose
<0.1	0	↔	↔	latente Hyperthyreose
0.28-4.2	*0*	↔	↔	*Euthyreose*
>10	0	↔	↔	latente Hypothyreose
>10	0	↔ / ↓	↓	manifeste Hypothyreose

0: TRH-Test nicht erforderlich

bTSH	ΔTSH	FT3	FT4	Funktion
mU/L	mU/L			
<0.1	0	↑	↔ / ↑	manifeste Hyperthyrose
<0.1	0	↔	↔	latente Hyperthyreose
0.1-0.28	<2.0	↔	↔	„low responder“
0.1-0.28	>2.0	↔	↔	Euthyreose
0.28-4.2	*0*	↔	↔	*Euthyreose*
4.2-10	↔	↔	↔	Euthyreose
4.2-10	↑	↔	↔	latente Hypothyreose
>10	0	↔	↔	latente Hypothyreose
>10	0	↔ / ↓	↓	manifeste Hypothyreose

0: TRH-Test nicht erforderlich

Antikörperbestimmung

- TSH-Rezeptorantikörper (TRAK)
- Antikörper gegen Schilddrüsenperoxidase (TPO-AK)
- mikrosomale Antikörper
- Antikörper gegen Thyreoglobulin

- Antikörpererhöhung bei Immunthyreopathie

TSH-Rezeptorantikörper (TSHRAb, TRAK)

- TSI Thyreoidea stimulierende Immunglobuline
  TSH-Wirkung führt zur Hyperthyreose
  TSI führen gemeinsam mit inflammatorischen Zytokinen zu metabolischen Veränderungen bei TSH-Rezeptor positiven Fibroblasten in der Orbita (endokrine Orbitopathie)
- TBAb Thyreoidea blockierende Antikörper
  keine TSH-Wirkung, blockieren die Bindung von TSH am Rezeptor und führen zur immunogenen Hypothyreose

Antikörper gegen Schilddrüsenperoxidase (TPOAK)

erhöht

- in 10% unspezifisch
- nahezu in 100% bei Patienten mit Immunhypothyreose
- in 80% der Patienten mit Mb. Basedow

Antikörper gegen Thyreoglobulin (TAK)

- geringe Erhöhung bei normaler Schilddrüsenfunktion möglich
- TAK-Titer korrelieren nicht mit TSH-Spiegel
- zusätzliche Information bei Verdacht auf AIT und negativen TPOAK
- wichtig in der Nachsorge des differenzierten Schilddrüsenkarzinoms
- können zu falsch niedrigen TG-Werten führen
- postoperativer TAK-Abfall entspricht niedriger Rezidivwahrscheinlichkeit
- TAK-Anstieg in der Nachsorge suspekt auf Rezidiv

Herzlichen Dank

für Ihre

Aufmerksamkeit!

www.schilddrueseninstitut.at

SCHILDDRÜSEN INSTITUT