Warum schauen unsere Bilder so unterschiedlich aus?

Mindestanforderungen an das szintigraphische Protokoll

Prim. Univ. Prof. Dr. Thomas Leitha

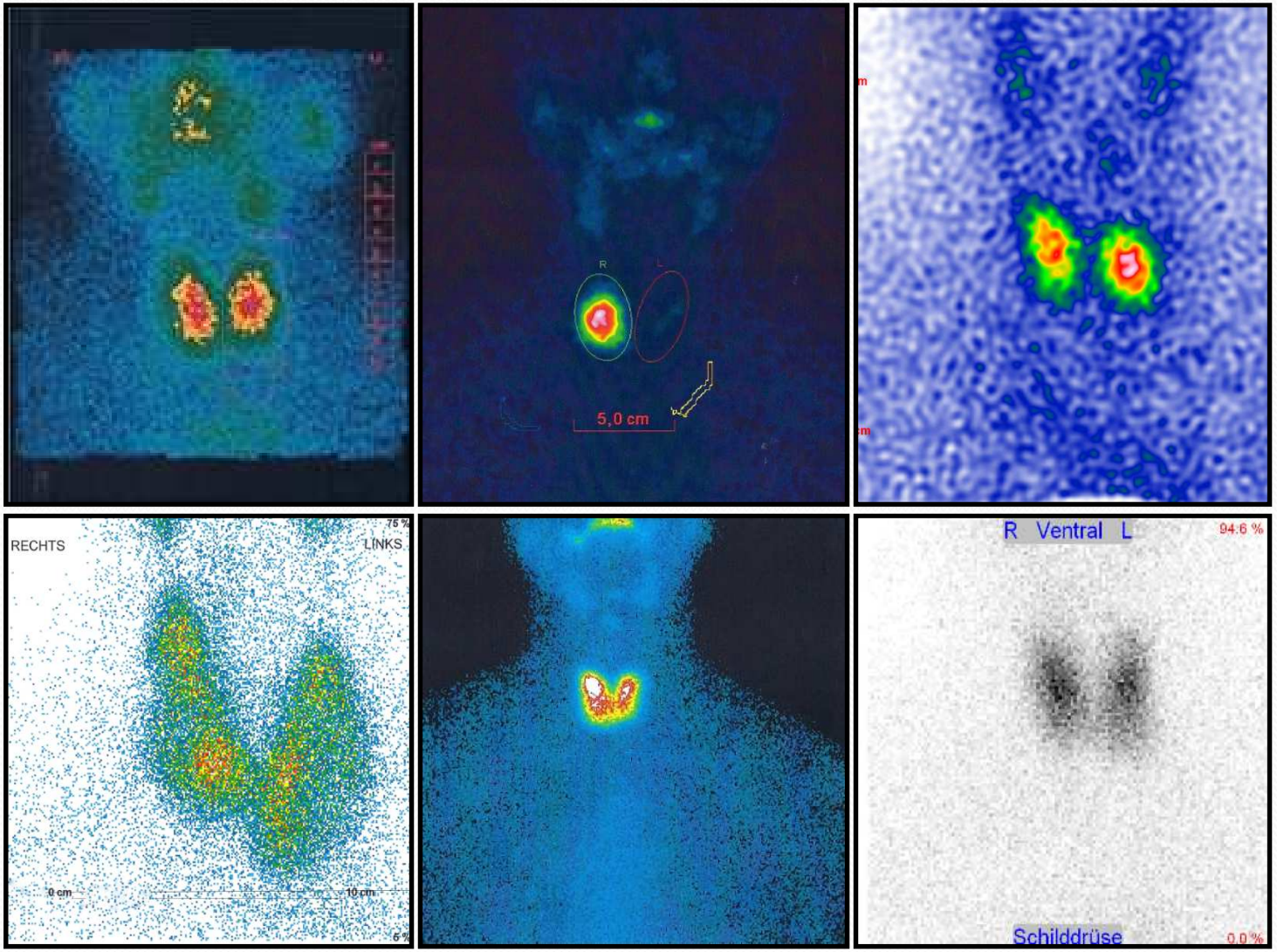

Bildmaterial z.T. aus *Sammlung G. Zettinig*

2011

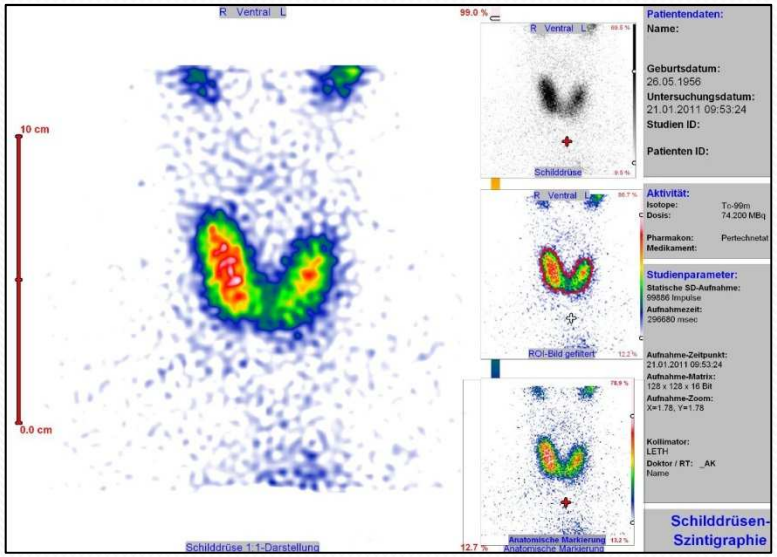

99.886 Impulse
297 sec

2011:

TSH	1.54 µU/ml	(0.25 – 4)
Freies T4	1.2 ng/dl	(0.8 - 1.8)
Freies T3	3.9 pg/ml	(1.8 - 4.2)

2014

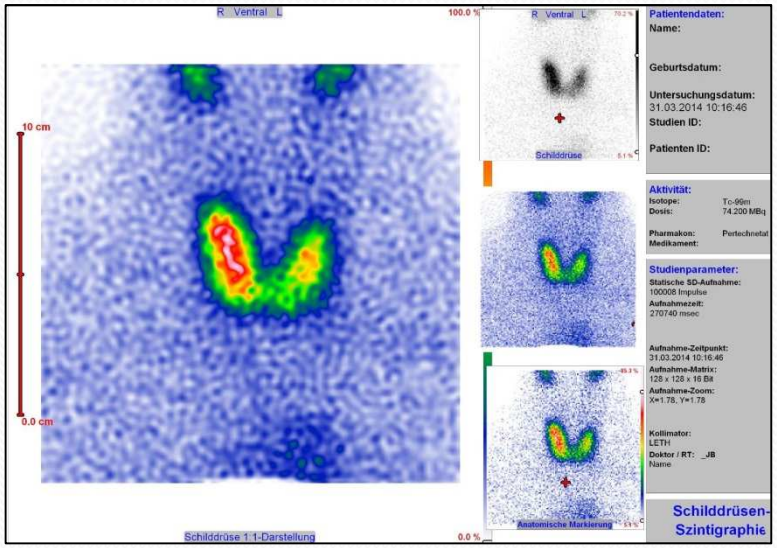

100.008 Impulse
270 sec

2014:

TSH	1.0 µIE/ml	(0.2 - 4.0)
freies T4	0.9 ng/dl	(0.8 - 1.8)
freies T3	3.2 pg/ml	(1.8 - 4.2)

2011

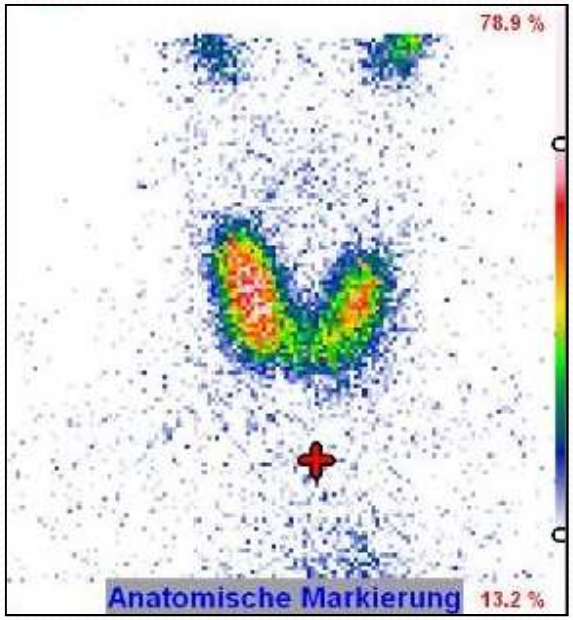

13,2 %

2014

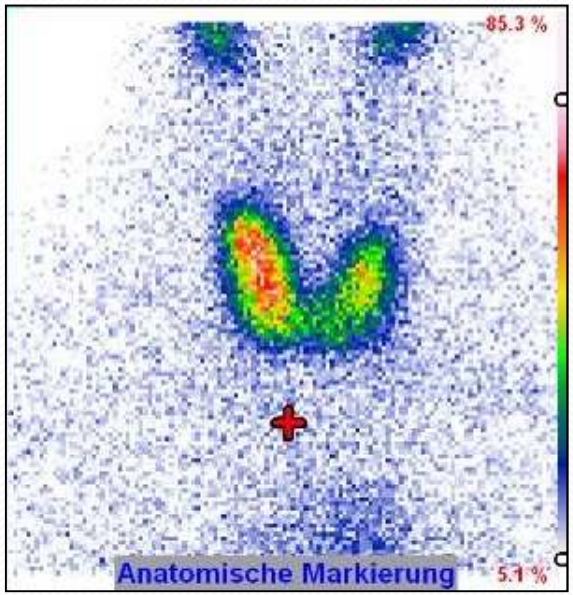

5,1 %

Was sagen die Guidelines?

- **OGN** ??
- **DGN = AWMF**
  - **Verfahrensanweisung für die Schilddrüsenszintigraphie** (Version 3) Version 2007
    - **AWMF**
      - **Verfahrensanweisung für die Schilddrüsenszintigraphie** 2007 S 1 (dzt. ungültig gesetzt)
  - **Einheitliche Standards für die Dokumentation von Szintigrammen** 1998, Update 2012
- **EANM** ??
- **SNM**
  - **Society of Nuclear Medicine Procedure Guideline for Thyroid Uptake Measurement** Version 3.0, approved September 5, 2006
  - **ACR–SNM–SPR PRACTICE GUIDELINE FOR THE PERFORMANCE OF THYROID SCINTIGRAPHY AND UPTAKE MEASUREMENTS** Revised 2009
- **AACE/AME/ETA Guidelines**
  American Association of Clinical Endocrinologists
  Associazione Medici Endocrinologi
  European Thyroid Association
  - **Medical Guidelines for Clinical Practice for the Diagnosis and Management of Thyroid Nodules** Endocr Pract. 2010; 16 (Suppl 1)

February 21, 2013

SNMMI SOCIETY OF NUCLEAR MEDICINE AND MOLECULAR IMAGING 1954–2014
CELEBRATING 60 YEARS

Physicians | Technologists | Scientists | Media | H

NEWS & PUBLICATIONS | MEMBERSHIP | EDUCATION | MEETINGS & EVENTS | ISSUES & ADVOCACY | QUALITY & PRACTICE

HOME > QUALITY & PRACTICE

In This Section

- Guidance
  - Procedure Standards
  - Appropriate Use Criteria
  - Dosimetry
  - Dose Optimization
- Quality
  - Phantom Program
  - PQRS
  - EHR Meaningful Use
  - Choosing Wisely
- Practice Resources
  - PET PROS
  - Credentialing
  - Practice Accreditation
  - Image Gently
  - Image Wisely
  - Scope of Practice
  - Webinars
  - Journals Articles
- Coding & Reimbursement
  - For Hospitals (APCs, IPPS)
  - For Private Practices (RBRVS)

Choosing Wisely

On February 21, 2013, SNMMI released a list of "Five Th
Question" in nuclear medicine and molecular imaging as
Wisely® campaign, led by the ABIM Foundation. The list
based recommendations that can support physicians an
about their care.

Each society participating in the campaign has develope
and Patients Should Question." By identifying specific te
specialty societies say are commonly used but not alway
respective fields, the societies aim to stimulate discussio
thereof—for many frequently ordered tests or treatment
patients.

SNMMI's list identified the following five recommendatio

- Don't use PET/CT for cancer screening in healthy ind
- Don't perform routine annual stress testing after cor
- Don't use nuclear medicine thyroid scans to evaluate
  normal thyroid gland function.
- Avoid using a computed tomography angiogram to d
  young women with a normal chest radiograph; consi
  study") instead.
- Don't use PET imaging in the evaluation of patients
  been assessed by a specialist in this field.

Choosing Wisely®
An initiative of the ABIM Foundation

View the full l
references.

The initiative
consumer-orie
Reports, AARP,
visit www.Choos

Don't use nuclear medicine thyroid scans to evaluate thyroid nodules in patients with normal thyroid gland function.

Warum schauen unsere Bilder so unterschiedlich aus?

WEIL EH EGAL IS?

BUT …

- Thyroid scintigraphy: an old tool is still the gold standard for an effective diagnosis of autonomously functioning thyroid nodules

Ianni F et al. J Endocrinol Invest. 2013;36(4):233-6

- TSH alone was not able to identify AFTN in 32% of the patients.

Indikationen

DGN 2007

- **Funktionstopographie** der Schilddrüse
- **TcTU und RITU** = Clearanceäquivalent zur Jodclearance

SNM 2009

- Thyroid **imaging** useful but not limited to:
  - Size and Location of thyroid tissue.
  - Evaluation of hyperthyroidism.
  - **Evaluation of suspected focal (i.e., masses)** or diffuse thyroid disease.
  - Evaluation of clinical laboratory tests suggestive of abnormal thyroid function.
  - Evaluation of patients at risk for thyroid neoplasm (e.g., post neck irradiation).
  - **Assessment of the function of thyroid nodules identified on clinical examination or ultrasound or by other diagnostic imaging.**
  - Evaluation of congenital thyroid abnormalities.
- **Thyroid uptake** is useful for:
  - DD hyperthyroidism from other forms of thyrotoxicosis (e.g., thyroiditis and thyrotoxicosis factitia).
  - Dosimetry

AACE/AME/ETA 2010

- **Role of scintigraphy in the diagnostic workup of thyroid nodules is limited in countries with iodine-rich diets.**
- **Regions with iodine deficiency, thyroid scintigraphy is used as part of the evaluation of patients with MNG.**
- For MNGs, **even without suppressed TSH**, to identify areas for FNA biopsy
- Large MNGs, especially with substernal extension: Diagnosis of ectopic thyroid tissue
- In Subclinical hyperthyroidism to identify occult hyperfunctioning tissue.
- **In follicular lesions to identify a functioning cellular adenoma that may be benign; however, most such nodules are cold on scintigraphy**
- To determine eligibility for radioiodine therapy
- To distinguish low-uptake from high-uptake Thyrotoxicosis

Key Recommendations AACE-AME-ETA

6.4.1. When to Perform Thyroid Scintigraphy

- Perform scintigraphy for a thyroid nodule or MNG if the TSH level is below the lower limit of the reference range or if ectopic thyroid tissue or a retrosternal goiter is suspected (**Grade B; BEL 3**)
- In iodine-deficient regions, consider performing scintigraphy to exclude autonomy for a thyroid nodule or MNG even if TSH is normal (**Grade C; BEL 3**)

6.4.2. How to Perform Thyroid Scintigraphy

- Either 123-I or 99m-TcO4 can be used for thyroid scintigraphy (**Grade B; BEL 3**)
- 131-I thyroid uptake is not recommended for routine diagnostic use unless low-uptake thyrotoxicosis is suspected (**Grade A; BEL 3**)

Kongenitale Hypothyreose

- Edgar J. Schoen et al. **The Key Role of Newborn Thyroid Scintigraphy With Isotopic Iodide (123I) in Defining and Managing Congenital Hypothyroidism *Pediatrics* 2004;114:e683–e688.**
- *Because our findings indicate that scintigraphy using technetium Tc 99m pertechnetate is valid only in the case of eutopic or absent thyroid, use of this technique may lead to an erroneous and clinically misleading finding of ectopic thyroid; 123I scintigraphy should therefore be preferred.*

CAVEATS

- Abklärung von Läsionen < 1 cm
- Abklärung von Zysten
- unnötige Scan Wiederholungen
- „postop. Restgewebe“ ohne Uptake
- Tc-Scan in der Nachsorge des differenzierten SD-CA
- Tc-Scan bei Verdacht auf SD Ektopie oder Agenese
-

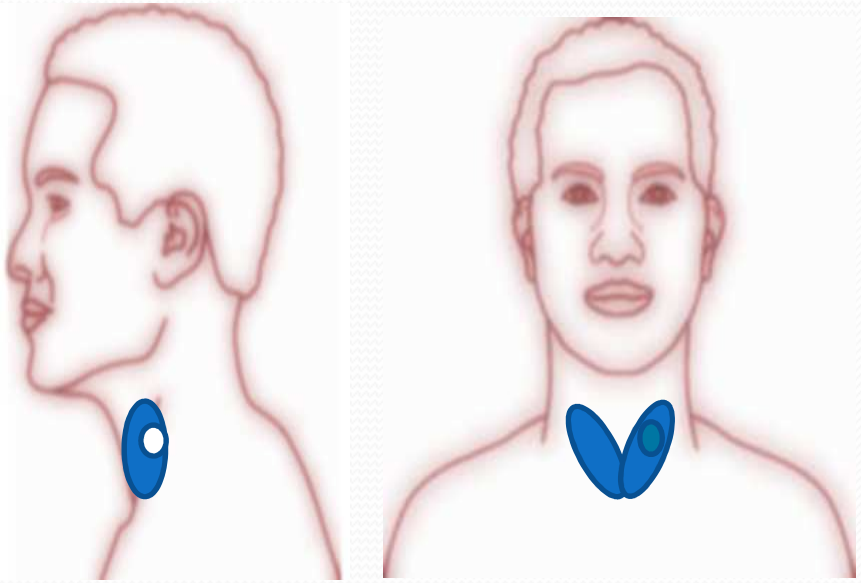

„Pseudofunktionelle Knoten“

CAVE: Malignomsuche

- 4% of hot nodules are shown to contain tumor, compared with 16% of cold nodules. Thus, radionuclide imaging is unreliable in excluding or confirming the presence of cancer.
  Daumerie C, Ayoubi S, Rahier J, et al. Prevalence of thyroid cancer in hot nodules. *Ann Chir*. 1998;52(5):444-8
- A literature review of surgical patients with solitary hyperfunctioning thyroid nodules managed by thyroid resection revealed an estimated 3.1% prevalence of malignancy. Compared to individuals with benign hyperfunctioning thyroid nodules, those with malignant hyperfunctioning nodules are younger and more predominantly female. Also, FTC and Hurthle cell carcinoma are found more frequently in hot nodules than in general.
  Mirfakhraee S, Mathews D, Peng L et al. A solitary hyperfunctioning thyroid nodule harboring thyroid carcinoma: review of the literature Thyroid Research 2013, 6:7
- "Cold" nodules represented cancer by biopsy or surgical pathology in 3 of 9 (33%) patients. A normal or "hot" TUS corresponded to benign pathology in 5 of 5 (100%) patients.
  Wilhelm SM. Utility of I-123 thyroid uptake scan in incidental thyroid nodules: an old test with a new role. Surgery. 2008;144(4):511-5.

CAVE: Substernale Struma

- The results show that most intrathoracic goiters do have thyroid function and that radioiodine scintigraphy is a definitive and cost-effective diagnostic procedure for this disease. We recommend that radioiodine scmntigraphy be the first study in the further evaluation of an anterior upper mediastinal mass seen on chest radiographs.
  Park HM. et al. Efficacy of Thyroid Scintigraphy in the Diagnosis of Intrathoracic Goiter AJR 1987 148:527-529

- Hemorrhage and cystic degeneration were observed within the nodule in the mediastinal thyroid component.
  Kahara T. et al. Mediastinal Thyroid Goiter with No Accumulation Intern Med 52: 2159, 2013

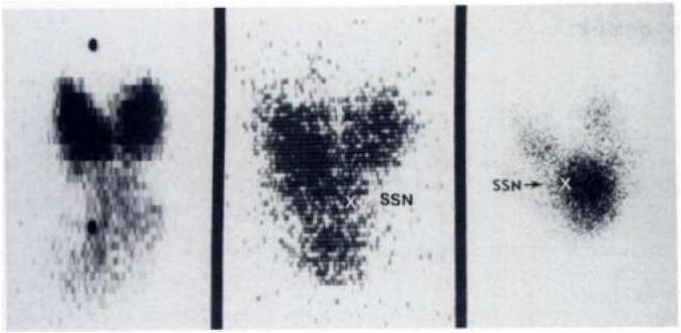

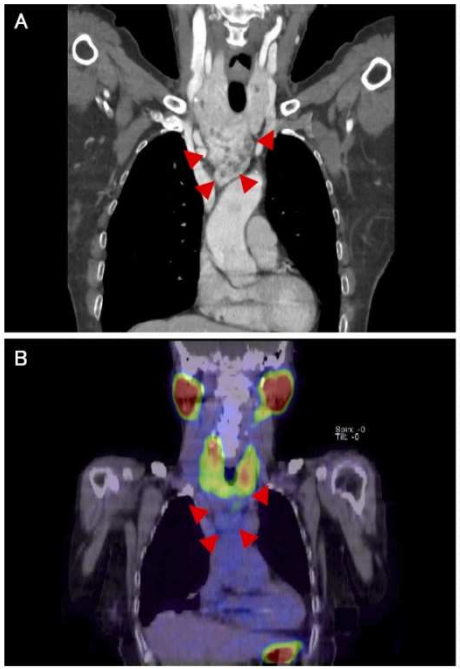

CAVE: Eindeutige AIT

- Of patients with a high or normal TSH, a radionuclide scan was inappropriately recommended in 11.5% of cases.

  Wanis K, Oucharek J, Groot G. Quality of thyroid referrals in Saskatchewan (Canada) Qual Prim Care. 2013;21(4):247-52.

There is room for improvement in pre-referral work-up of patients

Tracer

ÖStrSchV Referenzaktivität

Tc-99m-Pertechnetat:	110	MBq
I-123-Natriumiodid:	20	MBq

DGN

Tc-99m-Pertechnetat:	75	MBq (i.v.)
I-123-Natriumiodid:	10	MBq (i.v.)

SNM

2006

Tc-99m-Pertechnetat:	74-*370*	MBq (i.v.)
I-123-Natriumiodid:	*3,7-11,1*	*MBq (oral)*

2009 = ACR–SNM–SPR

Tc-99m-Pertechnetat:	74 -370	MBq (i.v.)
I-123-Natriumiodid:	*7,4-14,8*	*MBq (oral)*

Imaging

DGN

- mindestens **100.000 Impulse (10 Minuten)**
- *Ein Schluckverbot während der Aufnahme ist obsolet.*

SNM

- **pinhole collimator** (geometric distortions) additional parallel-hole collimator
- anterior and often both anterior oblique projections
- Minimum **100,000 counts or 8 minutes**
- Thyroid occupies most of the field of view.

Positionierung

Donauspital - Wien

www.epsom-sthelier.nhs.uk

Aufnahmezeitpunkt

- Tc-99m
  - 5 – 25 Minuten DGN
  - 5 – 30 Minuten SNM
- J-123
  - 2 – 4 Stunden DGN
  - 3 – 4 Stunden SNM

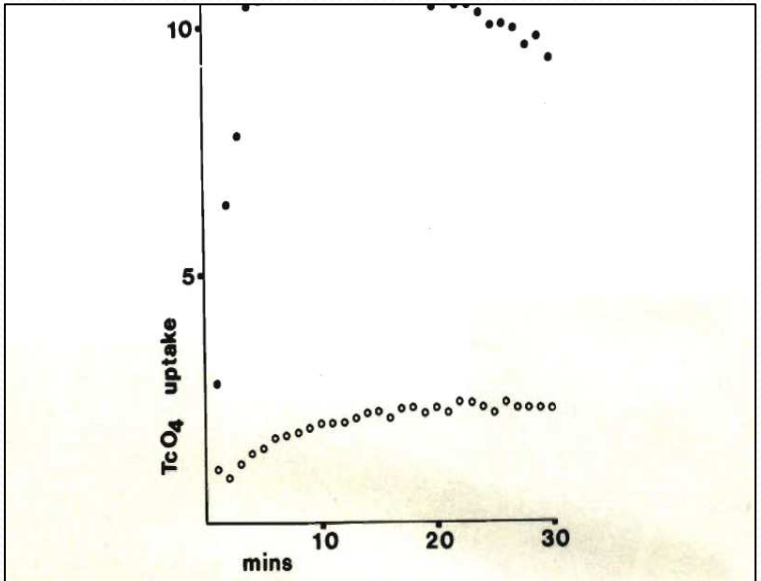

g. 6 : Pertechnetate thyroid uptake curve in euthyroid subject without goitre (open circles) and thyrotoxic patient (solid circles).

R. Hösch, T. M. D. Gimlette. Diagnostic Value of 20 Minute **99mTc Pertechnetate** Thyroid Uptake 1971

LIMBO: How low can you go …

DGN:

- Feldgröße von Gammakamera und verfügbarer Rechner-Matrix müssen aufeinander abgestimmt werden, so dass eine Auflösung von < 2 mm/Pixel gewährleistet ist.

www.nuklearmedizin.de

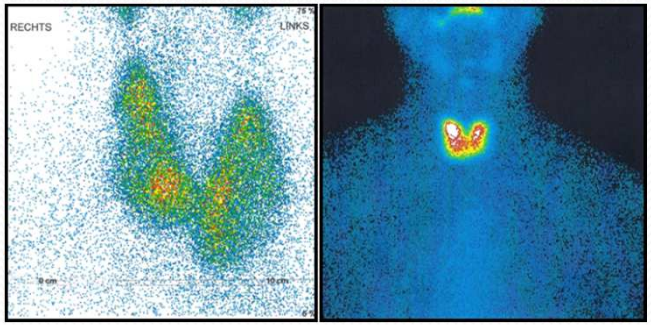

NEMA-Specification

Mediso Medical Imaging Systems

Available crystal thickness (mm)	6,5*	9,5	12,5	6,5*	9,5	12,5
Intrinsic spatial resolution						
CFOV FWHM (mm)	3,2	3,9	4,3	2,7	3,4	3,8
UFOV FWHM (mm)	3,3	4	4,4	2,8	3,5	3,9
System spatial resolution with collimator						
LEHR-Collimator FWHM (mm)	7,5	8,0	8,1	7,2	7,7	7,8
LEHR-Collimator FWTM (mm)	13,5	13,9	14,5	12,9	13,4	14,1

Name	Loch-länge (mm)	Loch-größe (mm)	Septen-dicke (mm)	Nominal-energie (keV)	Septen-penetration (%)	Kollimator gewicht (kg) TH-22/33	Kollimator gewicht (kg) TH-45	Geometrische Auflösung @10 cm (FWHM in mm) HP/UHP
LETH	35	1,9	0,2	140	1,1	14	19	8.0

Beispiel: Nucline TH-22

- Kristall 230*210 mm
- FOV 180*180 mm
- Matrix 128*128
- Pixel 1,4 mm
- SD Lappen 40*20*20 mm (= 8 ml)
- Pixel/SD 2D 2*29*14 = 812 Pixel
- 8 mm System Resolution: 6 Pixel = 1 (Bit) Information „normal/abnormal“
- In 2 SD Lappen: 812 Pixel = 135 Informationen (Bit)

1.067.089 Pixel

Die fünf Gründungsmitlieder der Österreichischen Schilddrüsengesellschaft beim ersten Treffen in Innsbruck am 4. Mai 2013. www.schildruesengesellschaft.at

Intrinsische Bit

Systemische Bit



CAVE: **Filter & Farbe**

oversampling

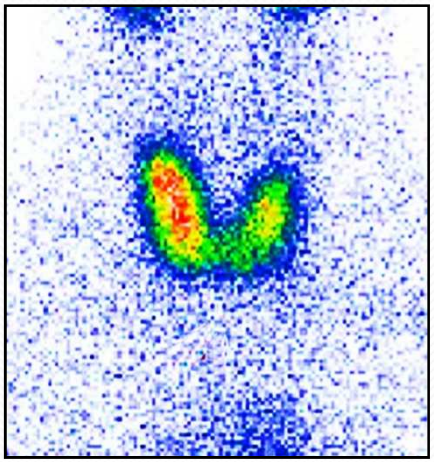

blurring

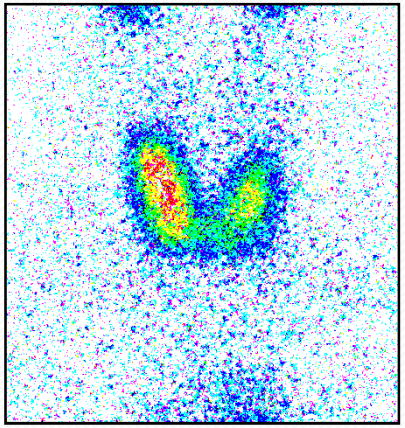

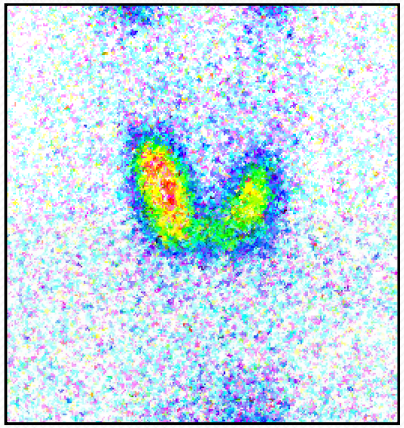

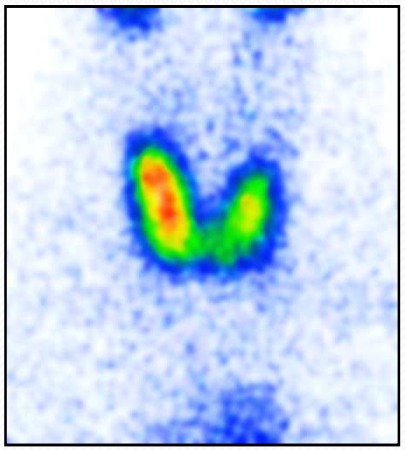

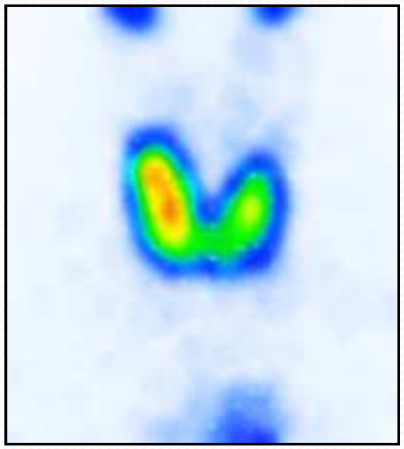



zu viel bunt ist ungesund …

Diskretisierung - Linearität



CAVE: UPTAKE

- Tägliche Konstanzprüfung
- Messung & Zerfallskorrektur der applizierten Aktivität
- Nachmessung der Spritze
- Detektorsensitivität
- Elektronisches Instabilität
- Kontaminationen
- Hintergrundzählrate
- Geometrie, Patientenposition (Detektor: Hals)
- Ungeeignetes Phantom
- Interferenz (Jodkontamination, Medikamente)

Adaptiert nach: SNM Procedure Guideline for Thyroid Uptake Measurement Version 3.0, approved September 5, 2006

Dokumentation DGN

- **Basisdokumentation** (1998=2012) Bohuslavizki et al. Nuklearmediziner 1989
  - durchführende Klinik/Praxis
  - Untersuchungsdatum
  - ***Farbbalken incl. Fenster***
  - zu jeder abgeleiteten Zahl wird die zugehörige ROI abgebildet
  - Befundungskritische Parameter werden für jede Untersuchung definiert und dann im Bild dokumentiert
  - spezielle Bildverarbeitungen einzelner Institutionen werden zusätzlich dokumentiert
- **Verfahrensanweisung 2007**
  - Patientendaten zur Identifikation
  - Bezeichnung des verabreichten Radiopharmakons
  - Verabreichte Aktivität in MBq
  - ***Aufnahmezeitpunkt relativ zur Applikation***
  - ***Messdauer in Minuten***
  - Schilddrüsenbild im Maßstab 1 : 1 mit Angabe des Maßstabes (cm)
  - ***Farbskala oder Grauwertskala über den gesamten Zählratenbereich***
  - ROI-Bild mit Darstellung der verwendeten ROI (Schilddrüse und Untergrund) (siehe Empfehlung der Arbeitsgemeinschaft Standardisierung der DGN)
- **Dokumentation Obligat** (1998 =2012)**:**
  - Applizierte Aktivität und Radiopharmakon
  - Jugulummarkierung
  - Standardisierte Seitenangaben
  - Uptake in Prozent der verabreichten Aktivität
- **Dokumentation Optional**:
  - Matrixgröße (z.B.: 128 x 128)
  - Maßstab (auch wenn 1:1)
  - Markierung und Beschriftung des Tastbefundes
  - ***Zeit zwischen Applikation und Aufnahme***

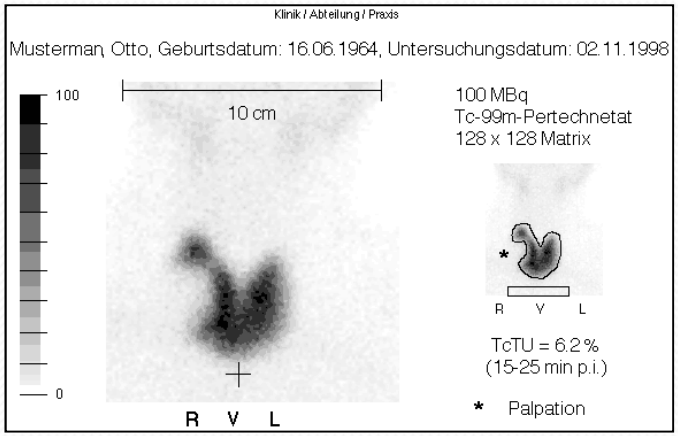

Dokumentation ACR–SNM–SPR

- Radiopharmaceutical
- Dose
- Route of administration
- other Pharmaceuticals

Compounds That May Decrease Thyroid Iodine Uptake

MEDICATION	TIME*
Adrenocorticosteroids	1 week
Bromides	1 week
Butazolidine	1 week
Mercurials	1 week
Methimazole (Tapazole)	1 week
Nitrates	1 week
Perchlorate	1 week
Propylthiouracil	1 week
Salicylates (large doses)	1 week
Sulfonamides	1 week
Thiocyanate	1 week
Tri-iodothyronine (Cytomel)	2 to 3 weeks
Thyroid extract (Synthroid, Proloid)	4 weeks
Iodine solution (Lugol's or SSKI**)	weeks
Iodine-containing antiseptics	weeks
Kelp	4 weeks
Some cough medicines and vitamin preparations	4 weeks
Intravenous contrast agents	1 to 2 months
Oil-based iodinated contrast agents	3 to 6 months
Amiodarone	3 to 6 months

*Time that patients should wait after medication is discontinued in order to obtain accurate uptake.

**saturated solution of potassium iodide.

subjektive Dos and Don‘ts

Dos

- Indikation: *Funktion*
- dedizierte SD Kamera
- *Markierung des Jugulums ???*
- Verhältnis Resolution : Matrix
- Lineare Skalen mitdrucken

Don‘ts

- Indikation: *Morphologie*
- keine LFOV Kamera

- Cave Glättung
- Fensterungen
- Größenangaben
- rein deskriptive Befunde

- Synopsis aus Scan und US

Markierung von Palpationsbefunden ???
Routine- Uptake ???

Danke für Ihre Aufmerksamkeit

rectilinear scanning analogous gamma-camera imaging gamma camera

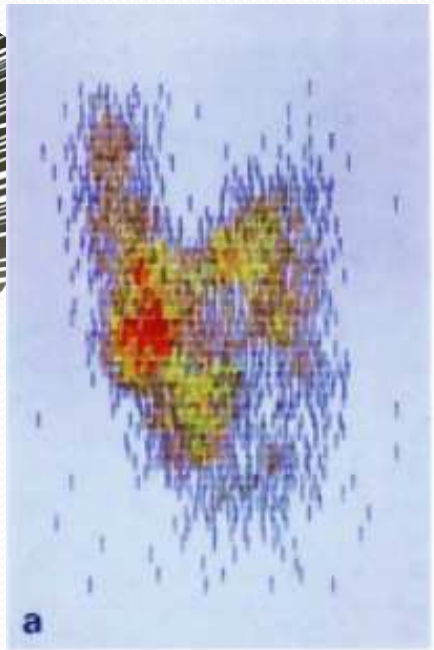

Bähre et al . Improved quality and information in thyroid scintigraphy. EJNM 1985, 11, 194-197