MEDIZINISCHE UNIVERSITÄT WIEN

Schilddrüse

Zytologie
Histologie
neue molekulare Marker

Oskar Koperek
Klinisches Institut für Pathologie
Medizinische Universität Wien

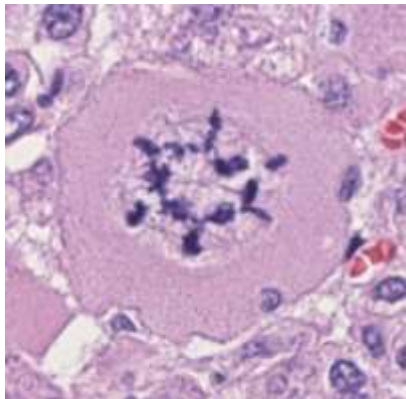

Punktionszytologie:

- Verlässliche Abklärungsmethode
- Sensitivität 57 - 98%
- Spezifität 71 – 100%
- reduziert OP Zahl um 50%
- reduziert die Kosten um 25%

N Engl J Med (2004): 351: 1764-71

Klinische Information

- Lokalisation
- Klinik (suspekt/ nicht suspekt)
- Wachstum
- Größe des Knotens
- Calcitonin
- Szintigraphie
- Sonographie
- bisherige Therapie
- Vorliegen einer Immunthyreopathie
- bekannte Malignome

MEDIZINISCHE UNIVERSITÄT WIEN

Allgemeines Krankenhaus
Währinger Gürtel 18-20 A-1090 Wien
Tel: +43 1 40 400 / 3650,3656 Fax +43 1 40 400 / 3707

KLINISCHES INSTITUT FÜR PATHOLOGIE

Schilddrüsenzytologie

Patientenetikett

Klinik: .....

zuweisender Arzt: .....

Grösse des Knotens (in cm): .....

Klinik
- ☐ suspekt
- ☐ nicht suspekt

Lokalisation

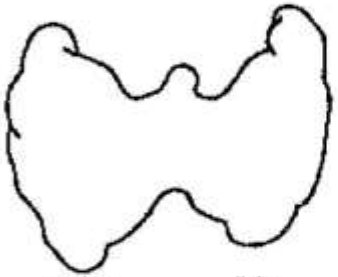

Szintigraphie
- ☐ heiss
- ☐ warm/indifferent
- ☐ kalt
- ☐ inhomogen

Schall
- ☐ echonormal
- ☐ echoarm
- ☐ echodicht
- ☐ gemischt echogen
- ☐ zystisch

weitere Angaben
- ☐ Wachstum
- ☐ Auto AK .....
- ☐ Malignom bekannt .....
- ☐ Calcitonin erhöht
- ☐ Thyreostatikatherapie
- ☐ .....

Datum: .....

Diagnosen

Histologie

- benigne
  - Entzündungen
  - Struma nodosa (noduläre Hyperplasie)
  - Follikuläres Adenom

- maligne
  - Follikuläres Karzinom
  - Papilläres Karzinom
  - Medulläres Karzinom
  - Wenig diff. Karzinom
  - Anaplastisches Karzinom
  - Metastasen

Zytologie

Thyreoiditiden

- Thyreoiditis Hashimoto
  - Lymphozyten
  - oxyphile Zellen

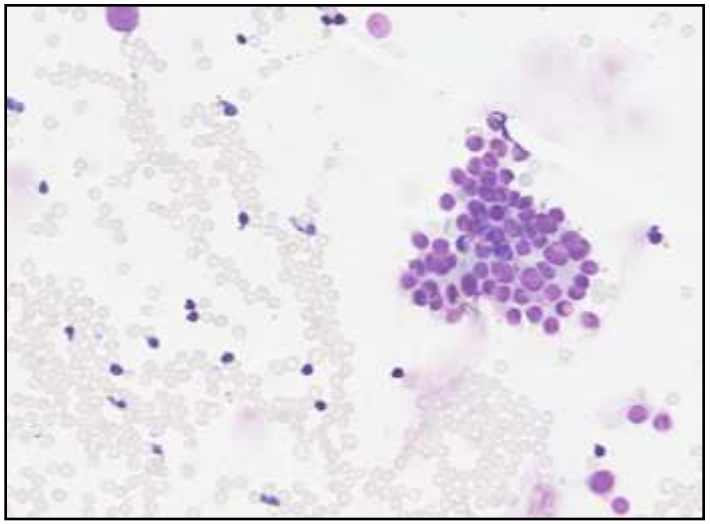

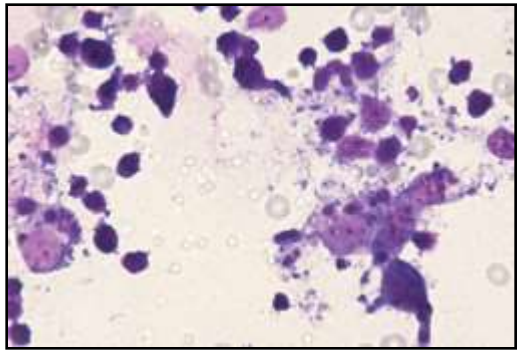

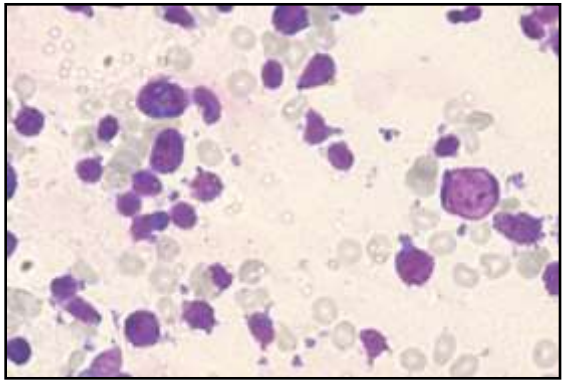

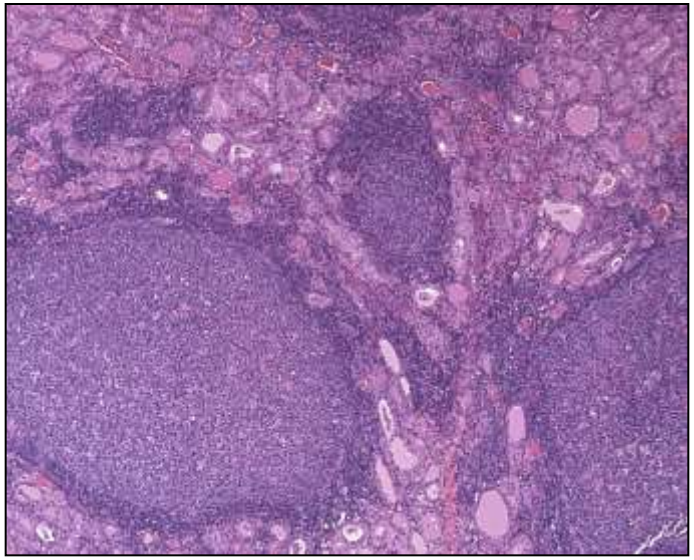

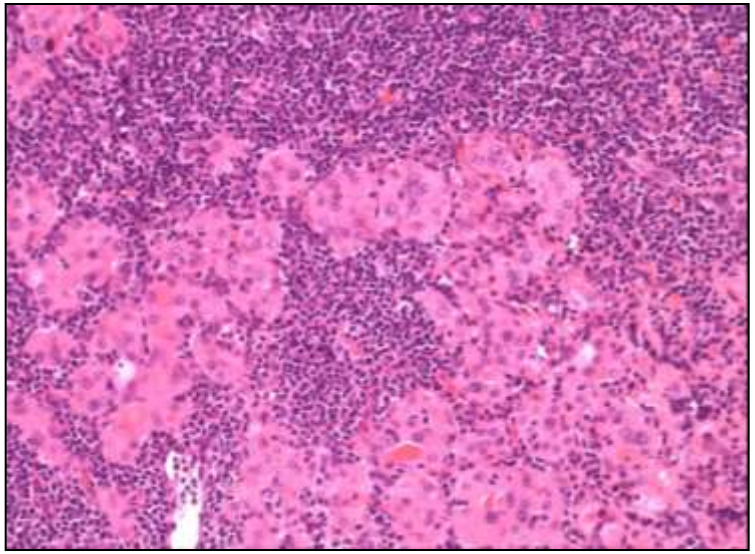

Thyreoiditiden

- Thyreoiditis De Quervain
  - Mehrkernige Riesenzell-Granulome um Kolloid

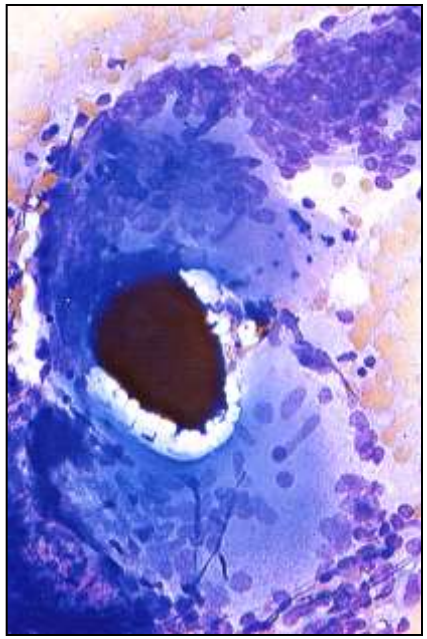

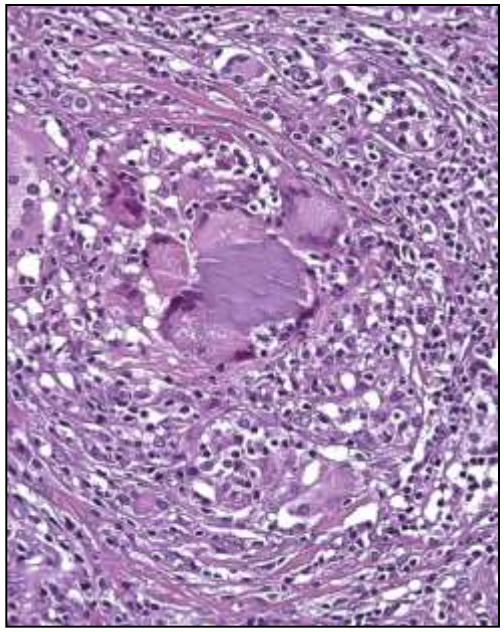

- Sklerosierende Thyreoiditis
  - Kein Zellmaterial

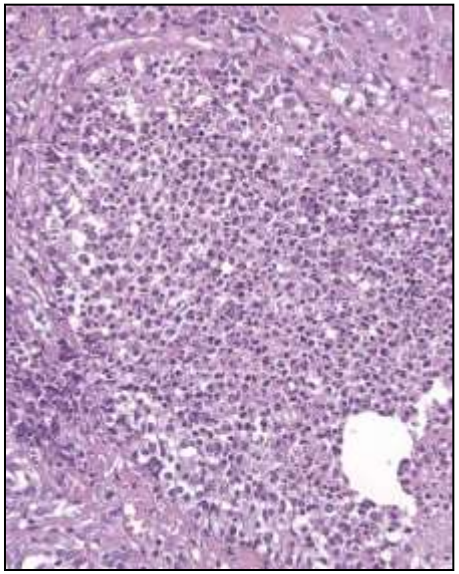

- Akute eitrige Threoiditis
  - Granulozyten, Zelldetritus Bakterien

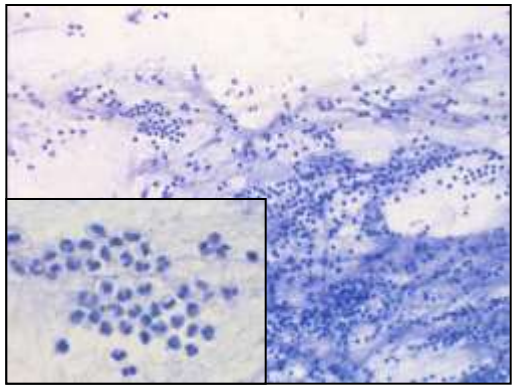

Benigne – Hyperplasie

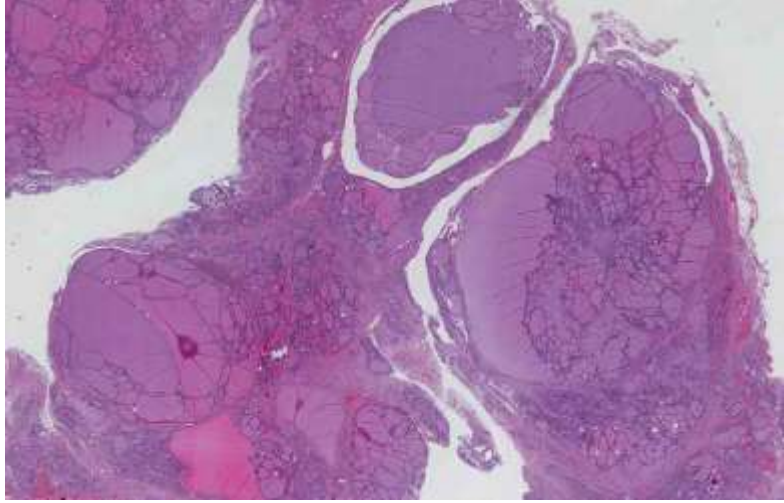

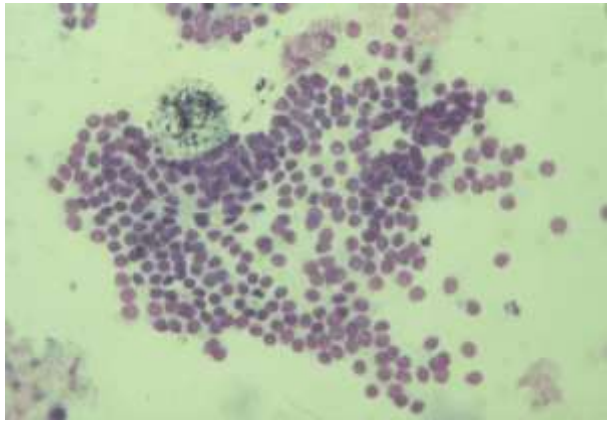

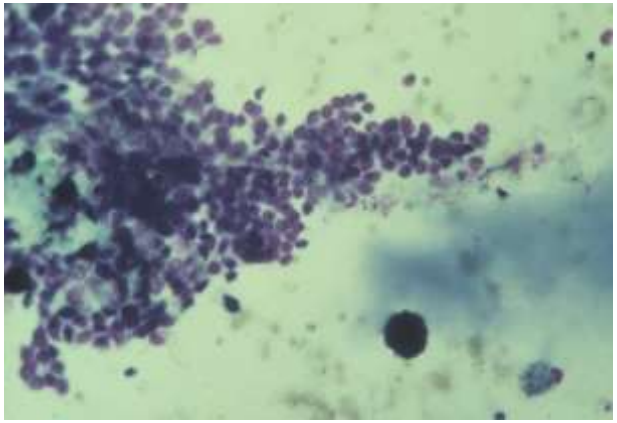

- kolloidreich
- Follikelepithelverbände unterschiedlicher Größe
- flächige Verbände
- regelmäßige Kernabstände
- isomorphe neben gering atypischen Zellen
- Regressive Veränderungen:
  - Beträchtliche Kernpolymorphie
  - Oxyphile Zellen (Onkozyten)
  - Lipidspeichernde Makrophagen
  - Cholesterinkristalle

Aus zytologischer Sicht keine Operationsindikation

Zytopathologische Diagnose

Histologie

- benigne
  - Entzündungen
  - Struma nodosa
  - Follikuläres Adenom

Zytologie

- benigne
  - Entzündungen
  - Hyperplasie

- maligne
  - Follikuläres Karzinom
  - Papilläres Karzinom
  - Medulläres Karzinom
  - Wenig diff. Karzinom
  - Anaplastisches Karzinom
  - Metastasen

Follikuläre Adenom vs. Karzinom

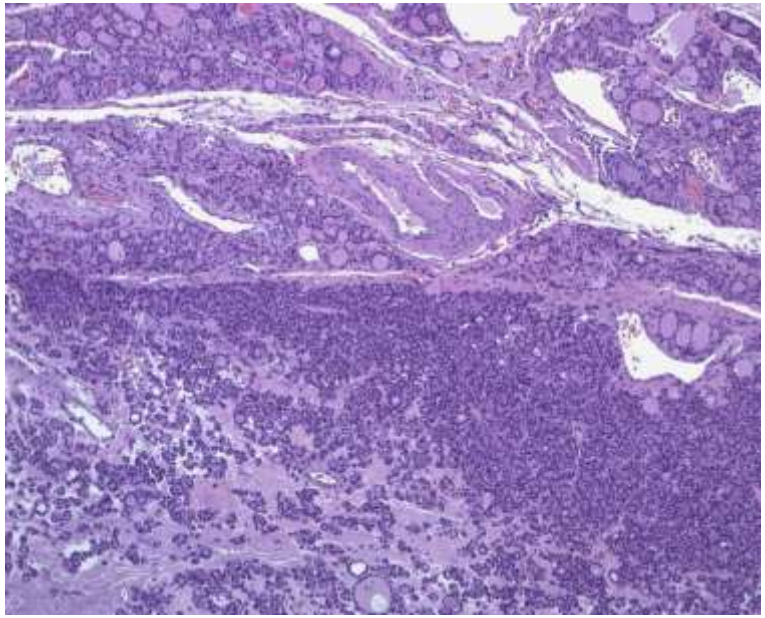

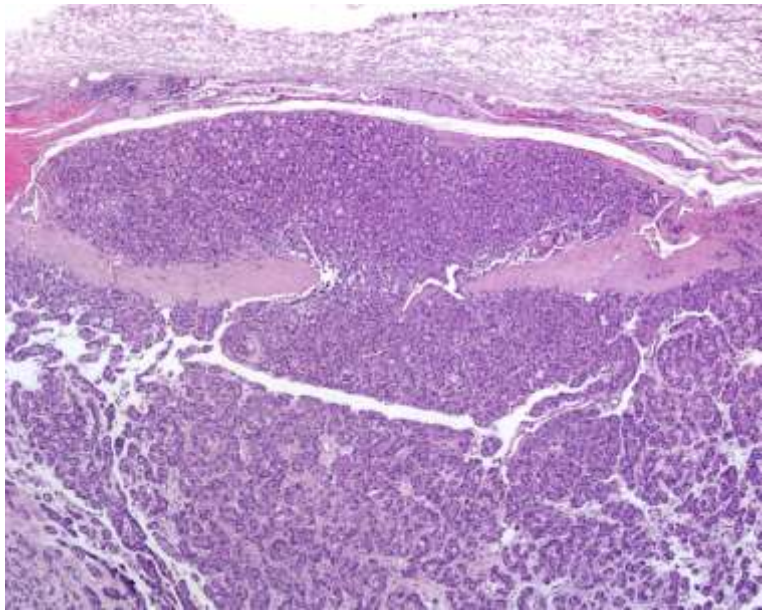

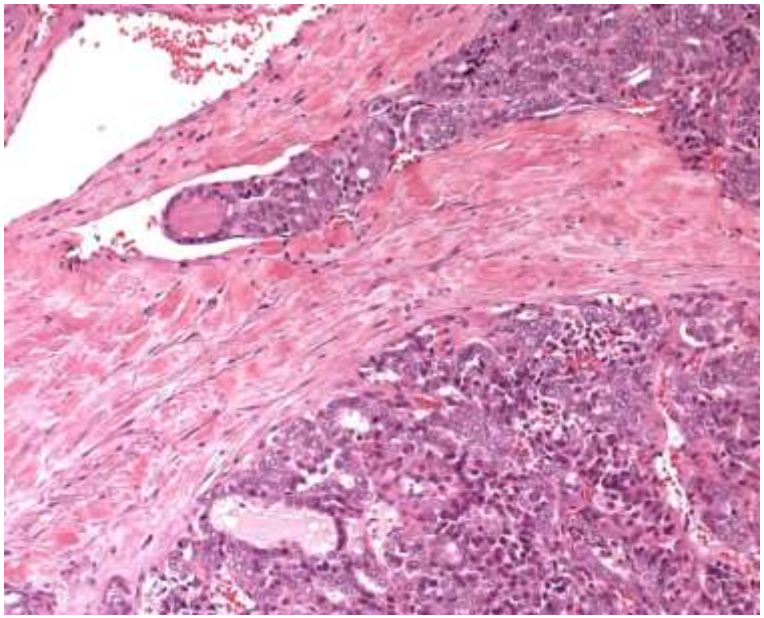

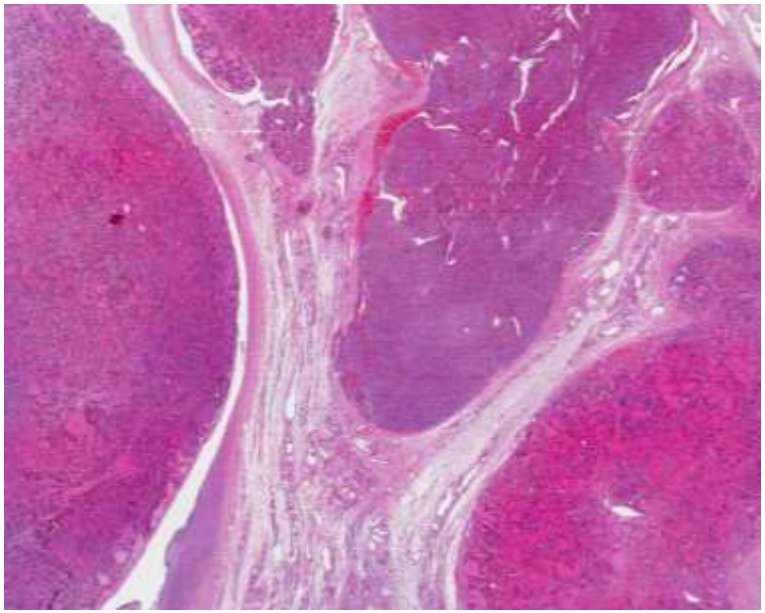

Follikuläre Neoplasie

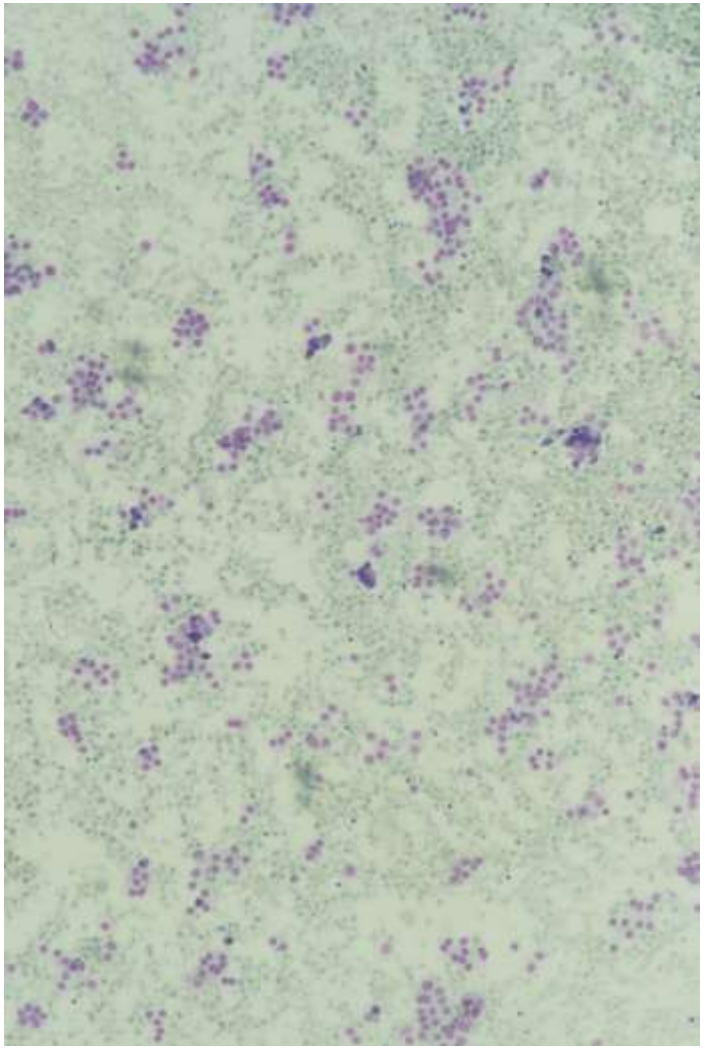

- Wenig oder fehlendes Kolloid
- kleinfollikuläre Epithelverbände
- Zellreichtum

Karzinome in 15 -30%

in der Regel eine Operationsindikation

Zytopathologische Diagnose

Histologie

- benigne
  - Entzündungen
  - Struma nodosa
  - Follikuläres Adenom
- maligne
  - Follikuläres Karzinom
  - Papilläres Karzinom
  - Medulläres Karzinom
  - wenig diff. Karzinom
  - Anaplastisches Karzinom
  - Metastasen

Zytologie

- benigne
  - Entzündungen
  - Hyperplasie
  - Follikuläres Adenom
- unklare Dignität
  - ***Follikuläre Neoplasie***

Papilläres Schilddrüsenkarzinom

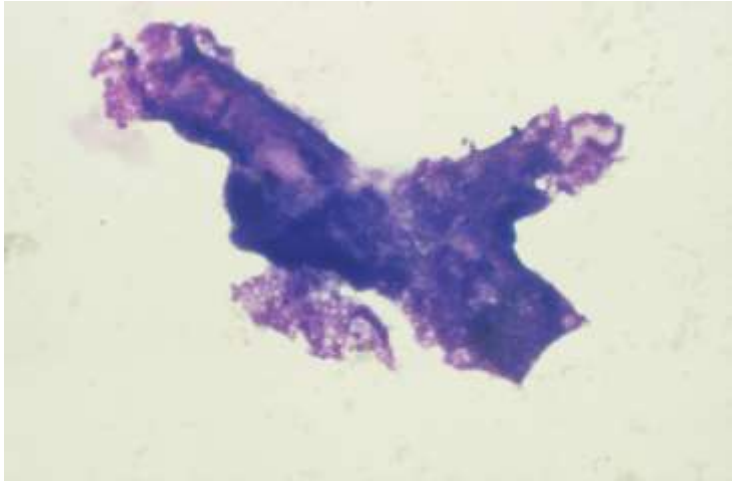

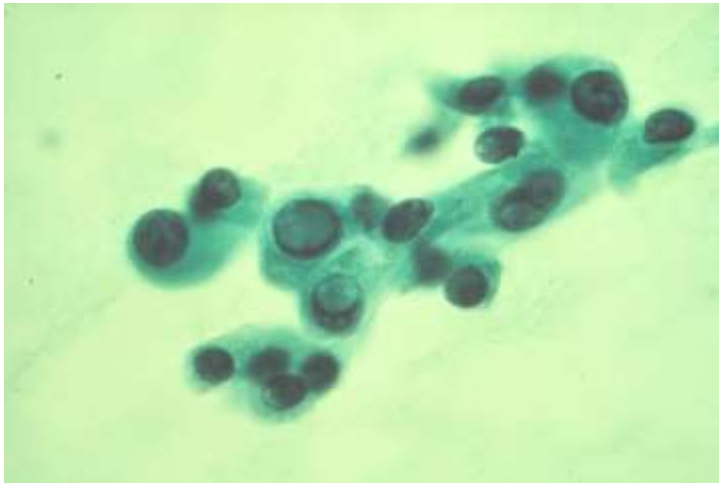

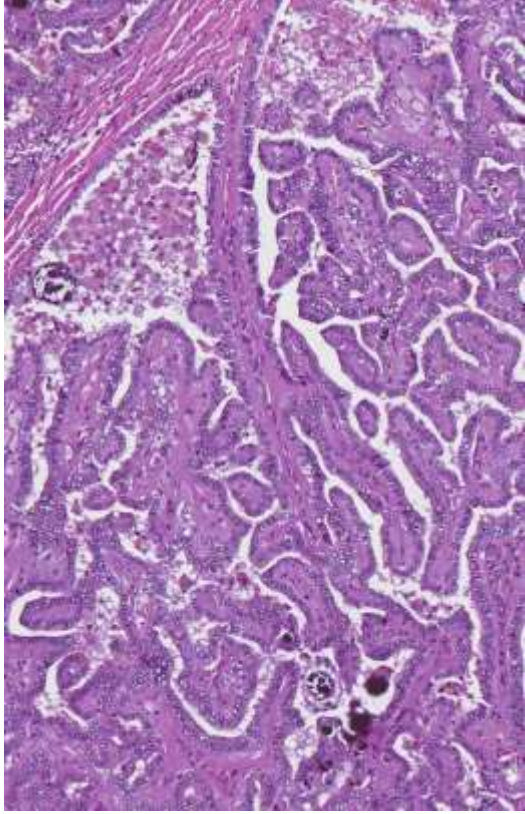

- Zellreichtum
- Kolloidarmut
- Papilläre Zellverbände
- Einschichtige Zellverbände
- Kernkriterien:
  - Kerneinschlüsse
  - Kernmembraneinfaltungen

Medulläres Karzinom

Serum-Calcitonin!

<u>Zytologie</u>

- Trianguläre Zellen
- Exzentrischer Kern
- Azurophile Granula im Zytoplasma
- Amyloid in 30%

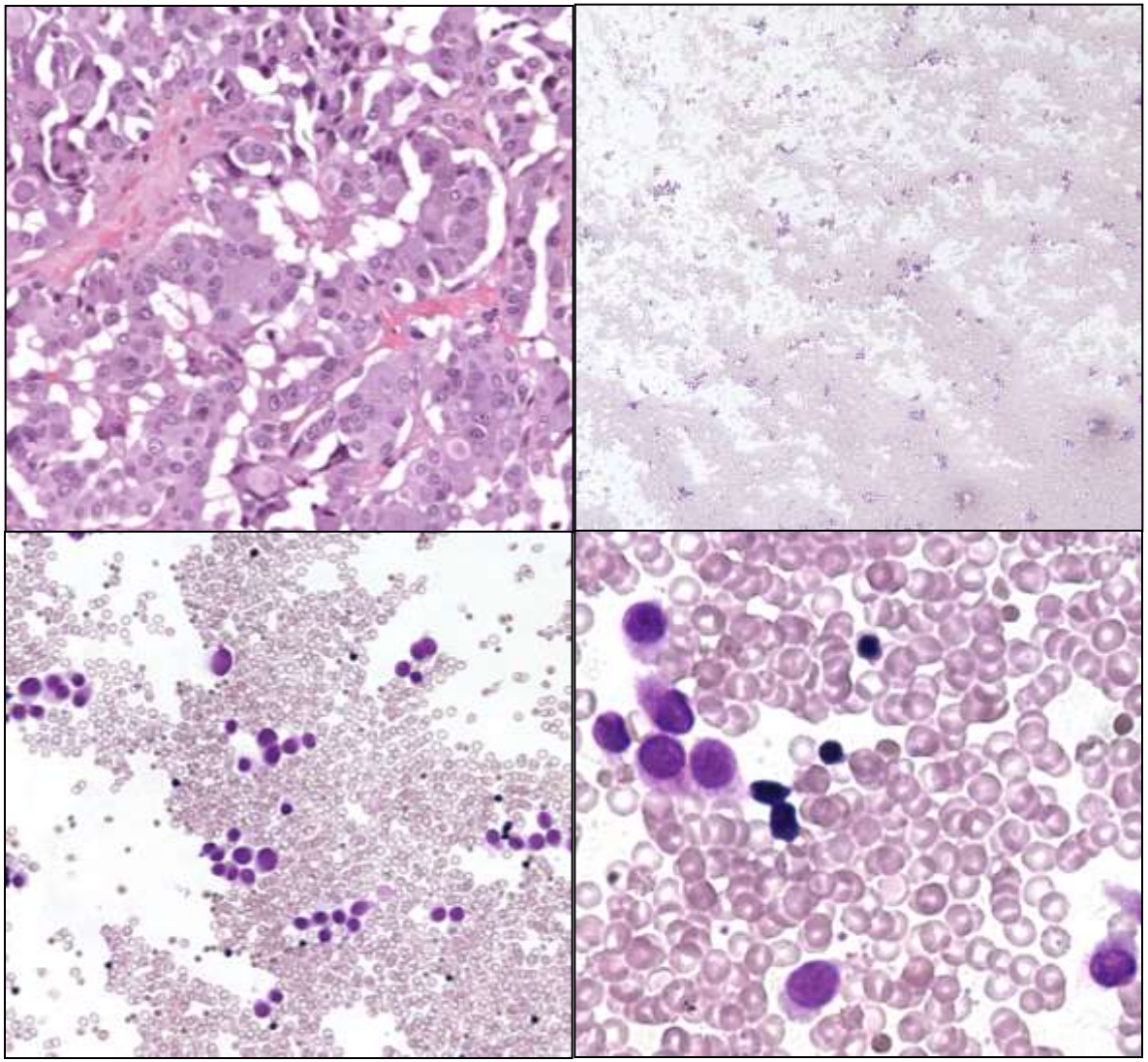

Wenig differenziertes Karzinom

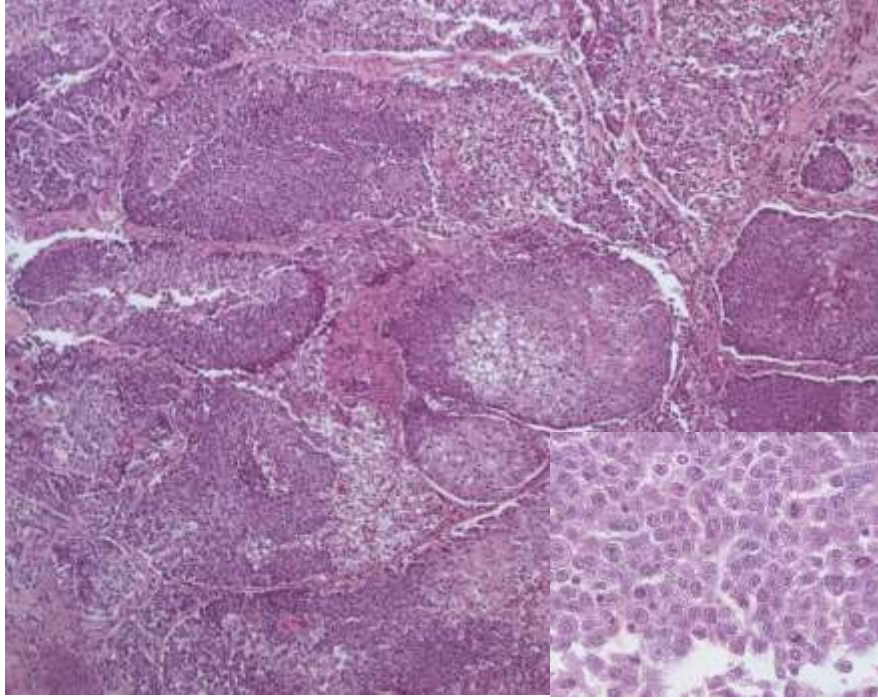

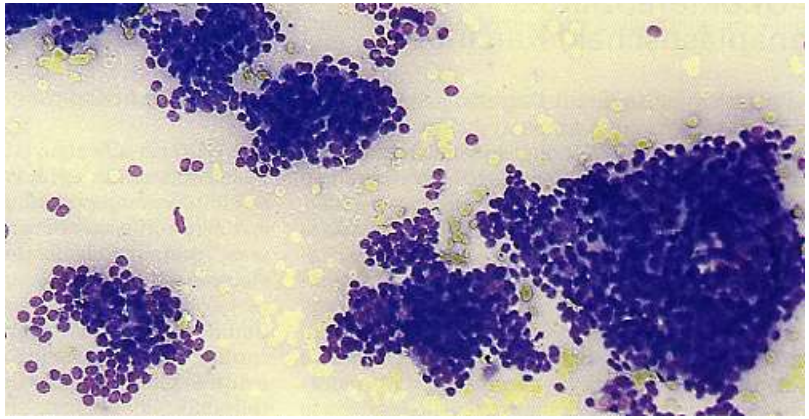

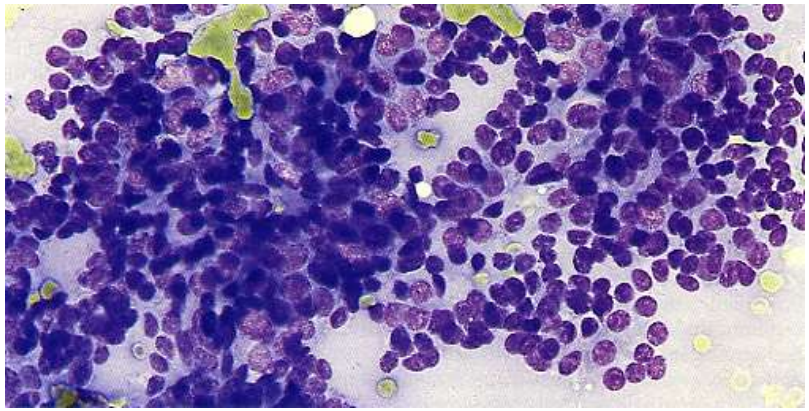

- zellreich, kein Kolloid
- solide Zellverbände
- dichte Lagerung der Kerne
- leichte- bis mittlere Atypien

DD: Follikuläre Neoplasie, Metastase

Undifferenziertes Karzinom

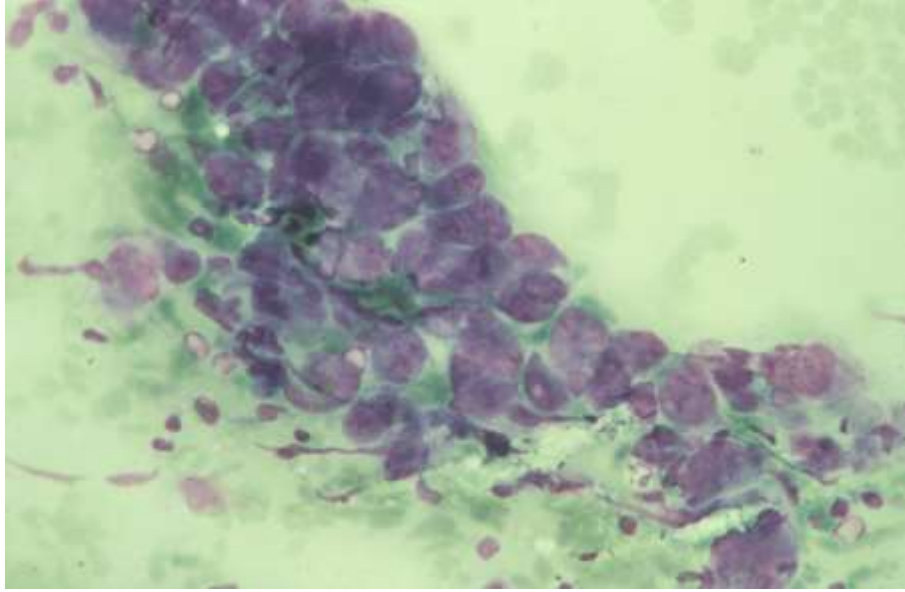

- Zellreichtum
- Kolloidarmut
- Ausgeprägte Zellatypien
- Polychromasie, Anisonukleose, Mitosen, Riesenzellen
- Nekrosen

  – Tritt vor allem im höheren Alter auf

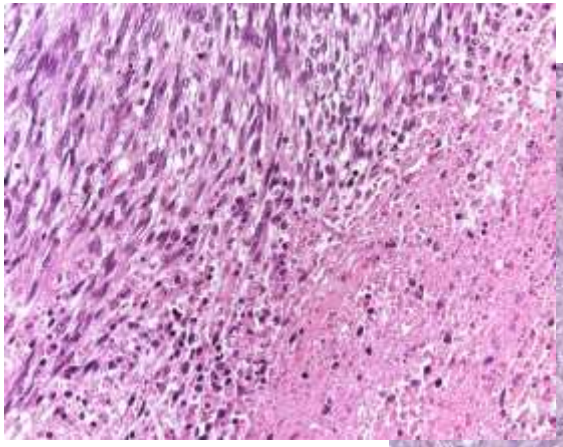

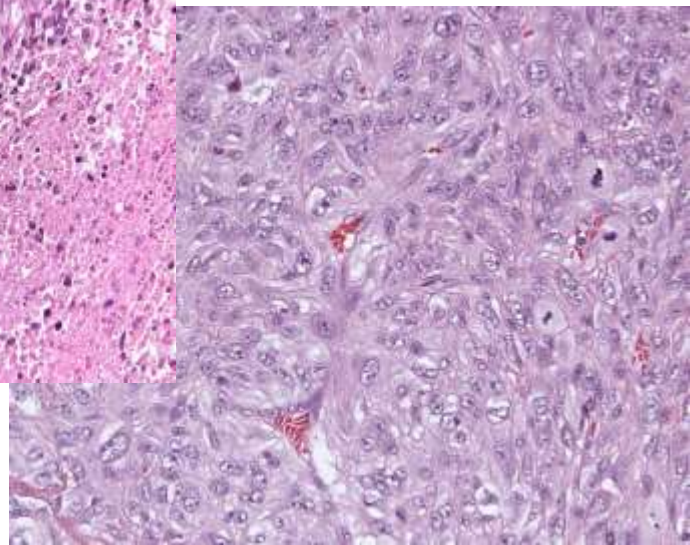

DD: Metastasen

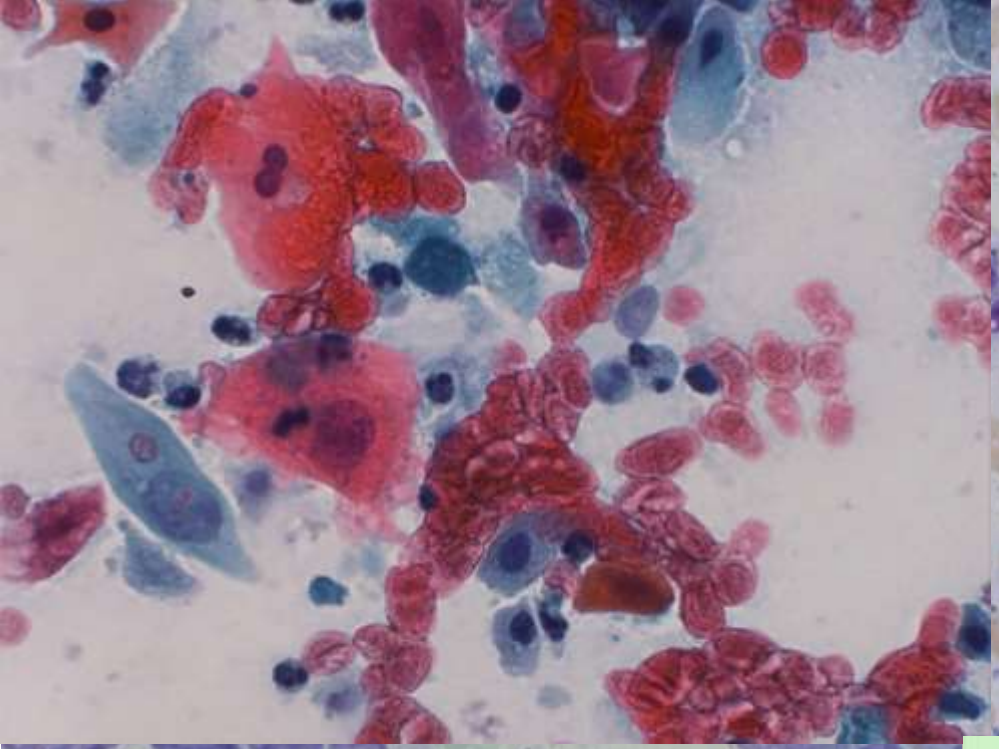

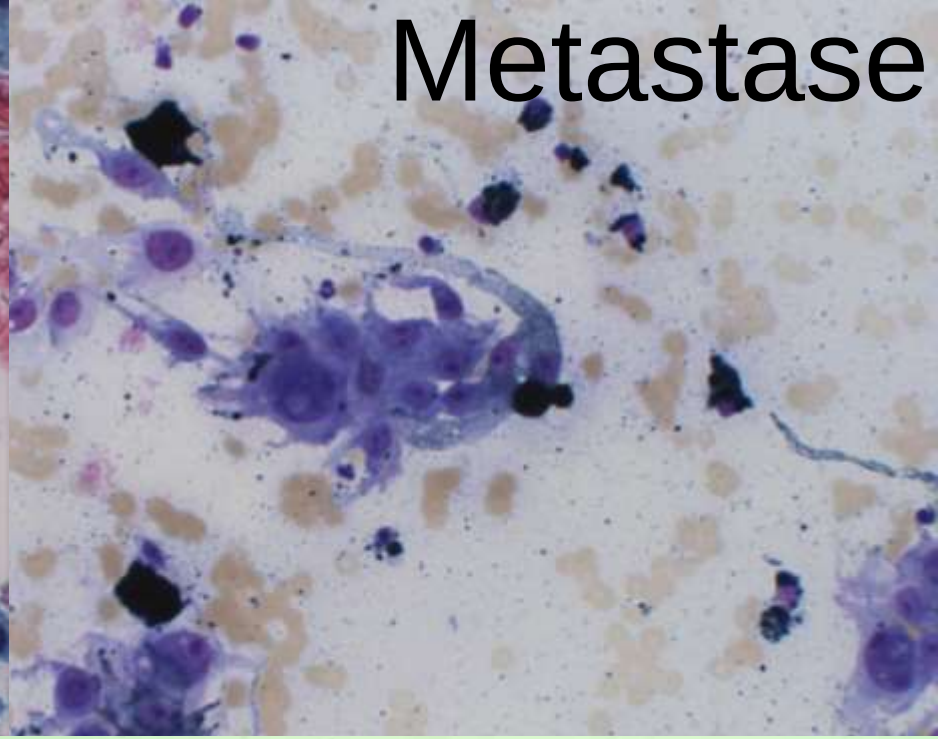

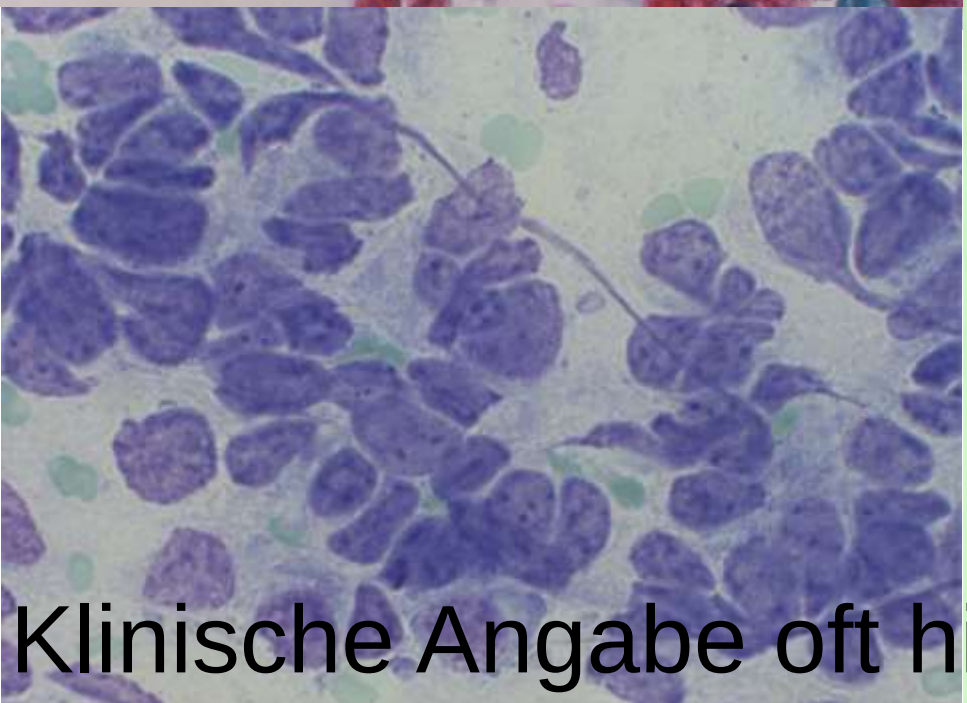

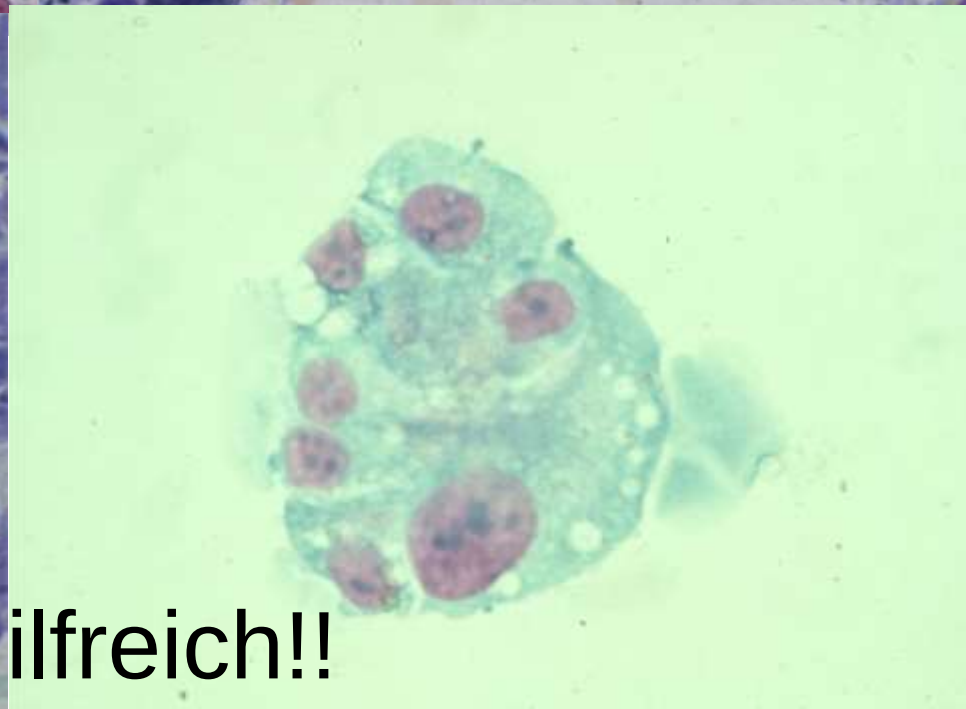

Klinische Angabe oft hilfreich!!

Zytopathologische Diagnose

Histologie

- benigne
  - Entzündungen
  - Struma nodosa
  - Follikuläres Adenom
- maligne
  - Follikuläres Karzinom
  - Papilläres Karzinom
  - Medulläres Karzinom
  - Insuläres Karzinom
  - Anaplastisches Karzinom
  - Metastasen

Zytologie

- benigne
  - Entzündungen
  - Hyperplasie
  - Follikuläres Adenom
- unklare Dignität
  - ***Follikuläre Neoplasie***
- maligne
  - Follikuläres Karzinom
  - Papilläres Karzinom
  - Medulläres Karzinom
  - Insuläres Karzinom
  - Anaplastisches Karzinom
  - Metastasen

Schilddrüsenzytologie in Österreich

- heterogen
- Es gibt derzeit keine Richtlinien durch entsprechende Fachgesellschaften
- übliche Diagnose/Klassifikationssysteme
  - Freitext Diagnosen ohne Klassifikation
  - PAP Klassifikation
  - ABC0 Klassifikation
  - Bethesda Klassifikation

Bewertung der Präparate

Gestaltung des Befundes (AKH-Wien)

- Beschreibung des Zellbilds
- Diagnose
  - Zytopathologische Diagnose (Freitext)
  - Angabe der Dignitätsbewertungsgruppe ABC0 (beinhaltet Aussage über Beurteilbarkeit)
  - (Angabe nach Bethesda Klassifikation)

Dignitätsbewertungsgruppe[1]

- Gruppe 0: nicht beurteilbar
- Gruppe A: kein Anhaltspunkt für Malignität
- Gruppe B: auffällig, unklare Dignität
- Gruppe C: maligne/hochgradig malignitätverdächtig

[1]:https://www.gesundheit.gv.at/Portal.Node/ghp/public/content/labor/referenzwerte/labor-schilddruesenzytologie.html

Dignitätsbewertungsgruppe

- Gruppe 0: nicht beurteilbar
- Gruppe A: kein Anhaltspunkt für Malignität
- Gruppe B: auffällig, unklare Dignität
  - Dig. B1: Follikuläre Neoplasie
  - Dig. B2: ein PTC nicht ausgeschlossen
- Gruppe C: maligne/hochgradig malignitätverdächtig

Histologie
bei Dignitätsgruppe B/C (2010-2013)

Patienten n= 110

ÖGZ	n (100%)	benign	maligne
B	59	38* (70%)	16 (30%)
B1	42	34* (81%)	8 (19%)
B2	17	4 (23,5%)	13 (76,5%)
C	51	1 (2%)	50 (98%)

* 3 papilläre Mikrokarzinome (3mm, 1,5mm, 0,5mm)

Dig. B1 (Follikuläre Neoplasie) - Histologie

- 8 Karzinome
  - 4 FTC
  - 3 PTC
  - 1 NOS-Karzinom

Dig. B2 Histologie: 13 PTC (davon 4 ≤1cm)

Dig. C - Histologie

- 50 maligne Tumoren
  - 38 PTC (davon 8 ≤ 1cm)
  - 3 MTC
  - 3 ATC
  - 1 NOS-Karzinom (als PTC befundet)
  - 5 Metastasen (Melanom, 2x PEC (Larynx, Cervix), kleinzelliges Karzinom, wenig diff Adenokarzinom)

Bethesda Klassifikation

- eigens für Schilddrüse entwickelte Klassifikation
- weitgehend evidenzbasiert
- international benützte Klassifikation

Bethesda 2009 Klassifikations gruppen

I. NONDIAGNOSTIC or UNSATISFACTORY

- Cyst fluid only
- Virtually acellular specimen
- Other (obscuring blood, clotting artifact, etc.)

II. BENIGN

- Consistent with a benign follicular nodule (includes adenomatoid nodule, colloid nodule, etc.)
- Consistent with lymphocytic (Hashimoto) thyroiditis in the proper clinical context
- Consistent with granulomatous (subacute) thyroiditis
- Other

III. ATYPIA OF UNDETERMINED SIGNIFICANCE or FOLLICULAR LESION OF UNDETERMINED SIGNIFICANCE

IV. FOLLICULAR NEOPLASM or SUSPICIOUS FOR A FOLLICULAR NEOPLASM

- specify if Hürthle cell (oncocytic) type

V. SUSPICIOUS FOR MALIGNANCY

- Suspicious for papillary carcinoma
- Suspicious for medullary carcinoma
- Suspicious for metastatic carcinoma
- Suspicious for lymphoma
- Other

VI. MALIGNANT

- Papillary thyroid carcinoma
- Poorly differentiated carcinoma
- Medullary thyroid carcinoma
- Undifferentiated (anaplastic) carcinoma
- Squamous cell carcinoma
- Carcinoma with mixed features (specify)
- Metastatic carcinoma
- Non-Hodgkin lymphoma
- Other

Bethesda Klassifikation

Terminology 2009	Risk of Malignancy (%)	Usual Management
Non Diagnostic or Unsatisfactory	**	Repeat FNA with US
Benign	0-3	Clinical Follow-up
AUS or Foll lesion of US	5-15	Repeat FNA
Foll Neoplasm or suspicious for a foll neoplasm (*specify if Hürthle cell (oncocytic) type)*	15-30	Surgical lobectomy
Suspicious for malignancy	60-75	Near-total thyroidectomy or surgical lobectomy
Malignant	97-99	Near-total thyroidectomy

Lokale Klassifikation und Bethesda 09

0: Nicht beurteilbar	→	I. Non diagnostic or Unsatisfactory
A: Kein Hinweis für Malignität (benign)	→	II. Benign
B: Unklar		
– B0: AUS/FLUS	→	III. AUS/FLUS
– B1: Follikuläre Neoplasie	→	IV. FN/ V.a. FN
– B2: „ein PTC kann nicht ausgeschlossen werden / V.a.“	→	V. Suspicious for Malignancy
C: Maligne	→	VI. Malignant

Bethesda Groups of Classification

I. NONDIAGNOSTIC or UNSATISFACTORY

- Cyst fluid only
- Virtually acellular specimen
- Other (obscuring blood, clotting artifact, etc.)

II. BENIGN

- Consistent with a benign follicular nodule (includes adenomatoid nodule, colloid nodule, etc.)
- Consistent with lymphocytic (Hashimoto) thyroiditis in the proper clinical context
- Consistent with granulomatous (subacute) thyroiditis
- Other

III. ATYPIA OF UNDETERMINED SIGNIFICANCE or FOLLICULAR LESION OF UNDETERMINED SIGNIFICANCE

IV. FOLLICULAR NEOPLASM or SUSPICIOUS FOR A FOLLICULAR NEOPLASM

- specify if Hürthle cell (oncocytic) type

V. SUSPICIOUS FOR MALIGNANCY

- Suspicious for papillary carcinoma
- Suspicious for medullary carcinoma
- Suspicious for metastatic carcinoma
- Suspicious for lymphoma
- Other

VI. MALIGNANT

- Papillary thyroid carcinoma
- Poorly differentiated carcinoma
- Medullary thyroid carcinoma
- Undifferentiated (anaplastic) carcinoma
- Squamous cell carcinoma
- Carcinoma with mixed features (specify)
- Metastatic carcinoma
- Non-Hodgkin lymphoma
- Other

Atypia of Undetermined Significance/ Follicular Lesion of Undetermined Sígnificance

- Cells with architectural and/or nuclear atypia insufficient degree of quality for any suspicious categories (e.g. suspicious for follicular neoplasm, suspicious for papillary thyroid carcinoma...).
- atypia are more marked than can be ascribed confidently to benign changes.

Atypia of Undetermined Significance/ Follicular Lesion of Undetermined Sígnificance
-
Scenarios

- Prominent population of microfollicles that does not fulfill the criteria of a „Follicular neoplasm/Suspicious for follicular neoplasm“
  - sparsely cellular lesion
  - „more prominent than usual population“ of microfollicles
- Predominance of Huerthle cells in a sparsely cellular aspirat with scant colloid
- Interpretation of nuclear atypia is hindered by sample preparation (e.g. air drying artefacts or clotting artefact)
- Nuclear features suggestive of a papillary carcinoma in an otherwise benign appearing sample (e.g. thyroiditis...)
- lymphoid infiltrate insufficient for „ suspicious for“ – repeat aspirate for flow cytometry is recommended.
- ....

Follicular Lesion of Undetermined Sígnificance - FLUS

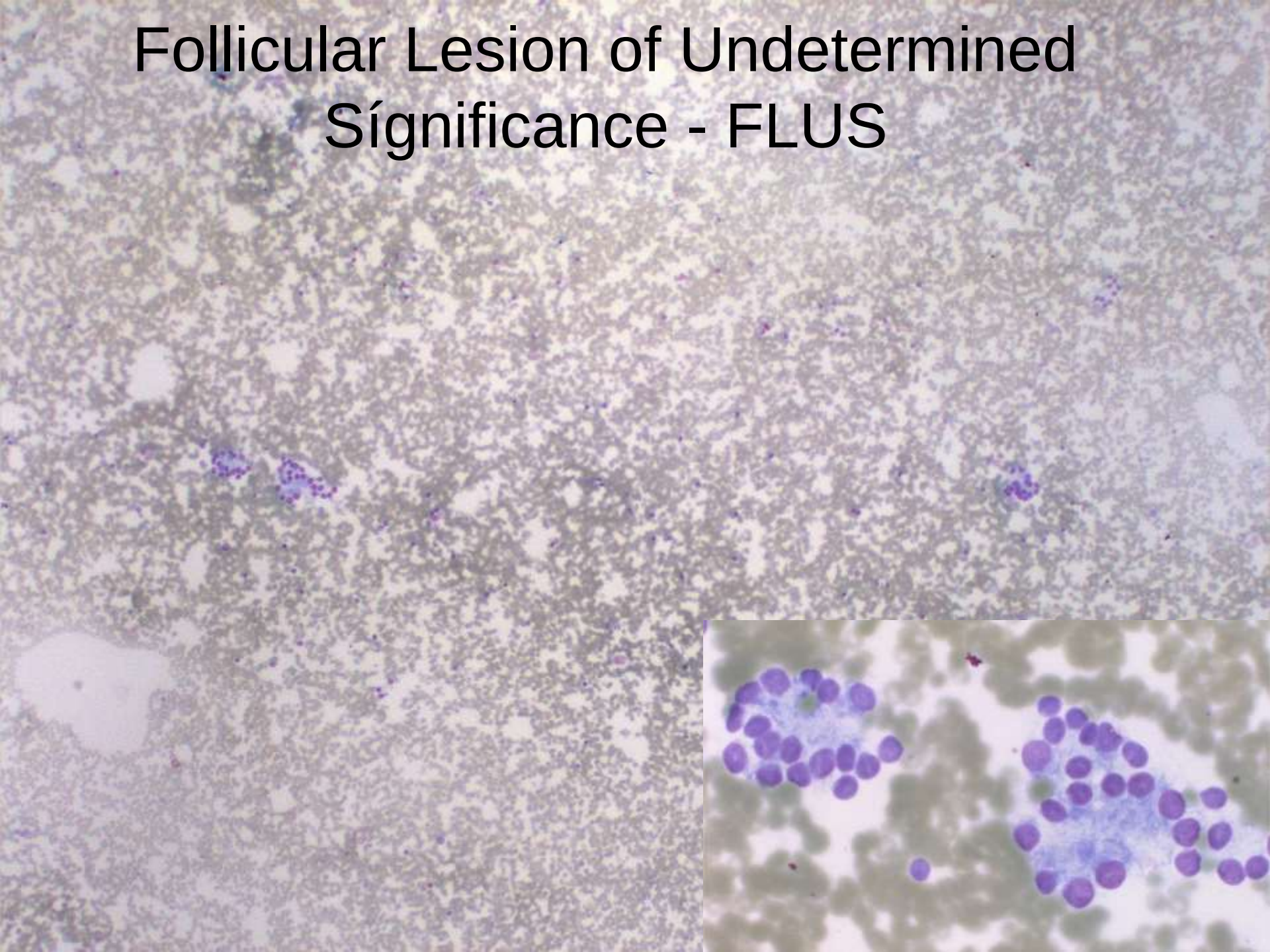

Atypia of undetermained significance - AUS

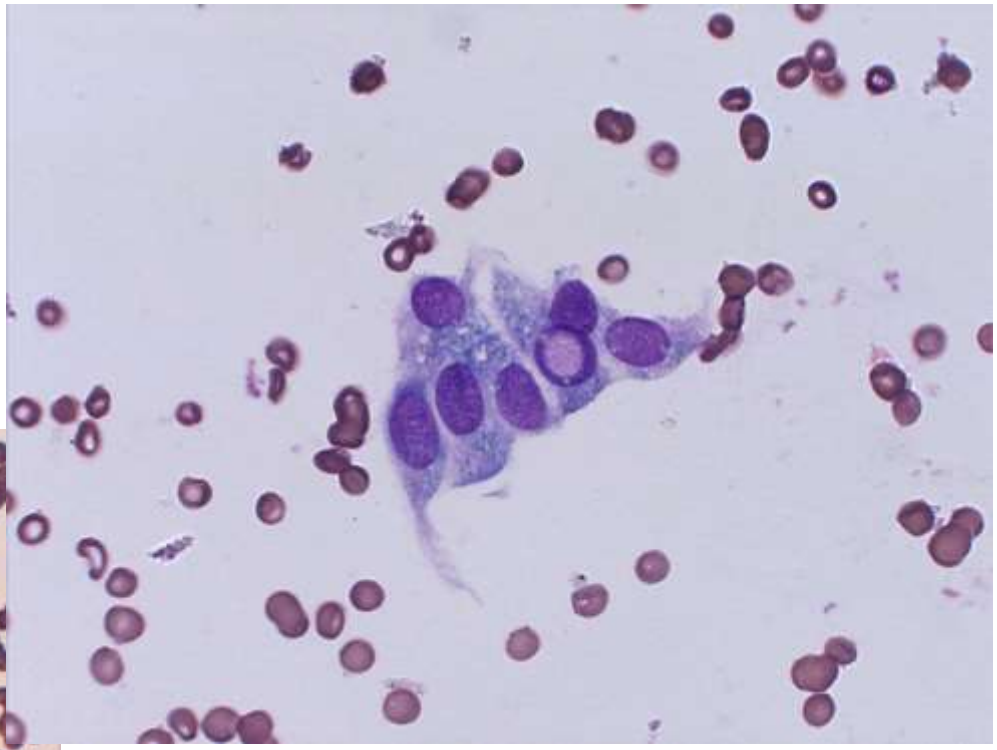

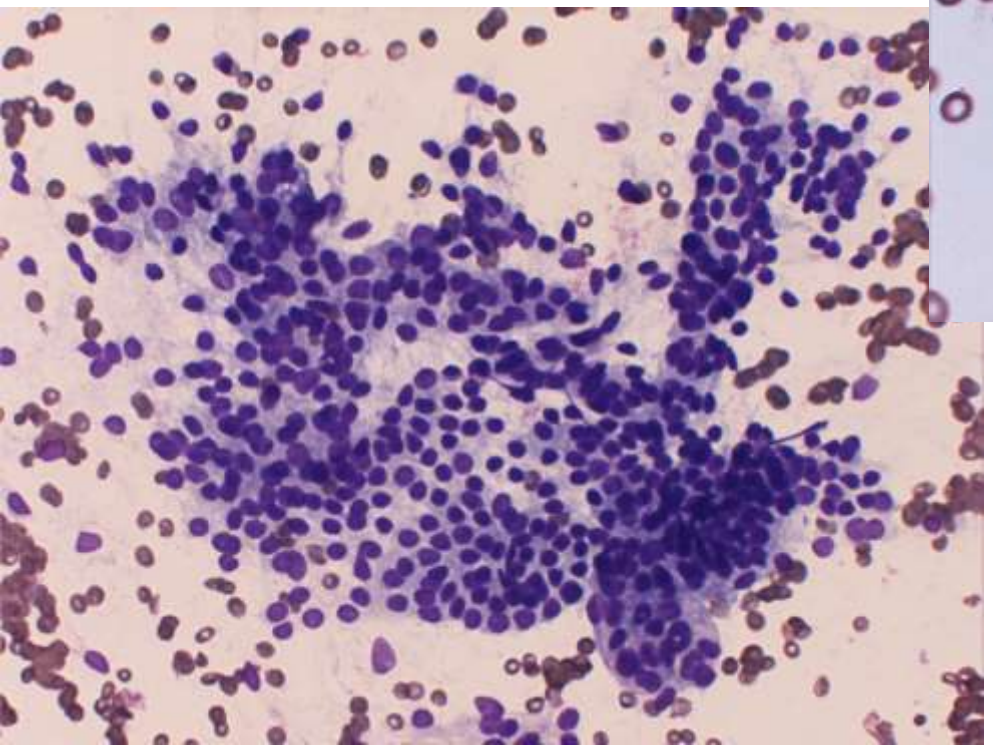

ungewöhnliches, lymphozytäres Zellbild

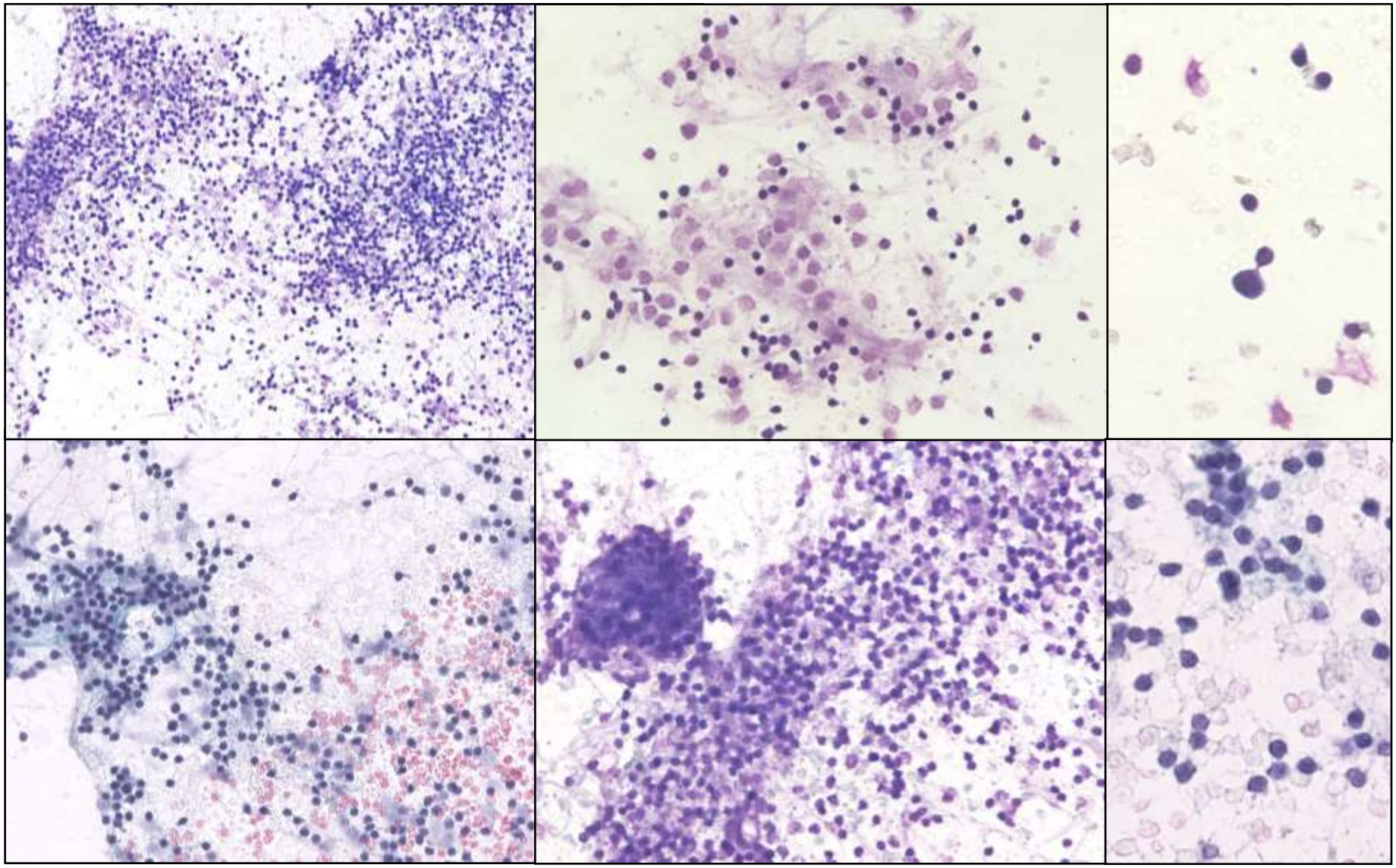

CAVE „AUS/FLUS“ !

- Schaffung eines Waste basket (nicht mehr als 7% aller Punktate!)

- hohe Interobservervariation in dieser Gruppe*!

* Cochand-Priollet B et al., „The **Bethesda** terminology for reporting **thyroid** cytopathology: from theory to practice in Europe.“, Acta Cytol. 2011;55(6):507-11.
Kocjan G et al., „The **interobserver** reproducibility of **thyroid** fine-needle aspiration using the UK Royal College of Pathologists' classification system.“; Am J Clin Pathol. 2011 Jun;135(6):852-9.

Molekularpathologie

Die Lösung für unklare zytologische Befunde?

Table 2. Correlation of Follicular Lesion of Undetermined Significance/Atypia of Undetermined Significance Diagnoses With Molecular Results and Surgical Pathology Outcome

Category	Surgical Pathology: Nonneoplastic	Surgical Pathology: Adenoma	Surgical Pathology: Papillary Carcinoma
All follicular lesion of undetermined significance/atypia of undetermined significance cases, n = 117	79/117 (70.1%)	18/117 (12.8%)	20/117 (17.1%)
Follicular lesion of undetermined significance/atypia of undetermined significance cases with *positive* molecular result, n = 12	0/12 (0%)	0/12 (0%)	12/12 (100%)[a]
Follicular lesion of undetermined significance/atypia of undetermined significance cases with *negative* molecular result, n = 105	82/105 (78.1%)	15/105 (14.3%)	8/105 (7.6%)[a]

[a]The difference between these 2 groups was statistically significant ($P < .001$).

Mutation	PTC Follicular Variant	PTC Classic	PTC Tall Cell
BRAF	0	2	1
NRAS61	7	0	0
HRAS61	1	0	0
PAX8/PPARgamma	1	0	0

[a]There were no *KRAS*, *RET/PTC1*, or *RET/PTC3* positive results.

Contribution of Molecular Testing to Thyroid Fine-Needle Aspiration Cytology of ‘‘Follicular Lesion of Undetermined Significance/Atypia of Undetermined Significance’’
N. Paul Ohori et al., Cancer Cytopathology February 25, 2010

Table 2. Summary of Major Molecular Genetic Changes Associated With Thyroid Neoplasms

Mutation/ Rearrangement	Associated Tumors	Frequency by Tumor Type (%)	Pathway Impact or Point of Action	Benign Lesions
Ras	Follicular	45	MAP kinase	Adenoma (30%)
	Papillary	10		Nodular goiter (5%)
	Poorly differentiated	35		
	Anaplastic	50		
PAX8/PPARG1	Follicular	30-40	PPARγ1	Adenoma (7%)
	Papillary (FV)	5		
GRIM19	Hurthle cell		Apoptosis	
BRAF	Papillary (classic)	45	MAPK, ERK	Adenoma (rare)
	Poorly differentiated	20		
	Anaplastic	20		
RET/PTC	Papillary	20	RTK receptor	
PIK3CA	Follicular	<10	PI3K/AKT	
	Anaplastic	20		
PTEN	Follicular	<10	PI3K/AKT	
	Anaplastic	>10		
TRK	Papillary	< 5	NTRK receptor via MAPK	
CTNNB1	Poorly differentiated	20		
	Anaplastic	60		
TP53	Poorly differentiated	20	Cell division G1→S	
	Anaplastic	70		
APC	Papillary	< 5		

Lewis A. Hassell et al, Cytologic and Molecular Diagnosis of Thyroid Cancers Is it Time for Routine Reflex Testing? Cancer Cytopathology February 25, 2012

Table 3 Survey of *RET/PTC* expression in cytology samples with definitive histology diagnosis. Data are presented as sample numbers and (%). RT-PCR was visualized by ethidium bromide.

	Histology	RT-PCR	SB on RT-PCR	Q-PCR
Cheung *et al.* (14)	PTC		16/33 (48.5)	
	B		0/39	
Domingues *et al.* (15)	PTC	3/11 (27.2)		
	B	1/11 (9.1)		
Sapio *et al.* (79)	PTC	1/6 (16.7)		
	B	0/72		
Pizzolanti *et al.* (13)	PTC	0/33		
	B	0/32		
Nikiforov *et al.* (16)	PTC			5/40 (12.5)
	B			0/38
Cantara *et al.* (11)	PTC		11/74 (14.9)	
	B		0/165	
Musholt *et al.* (80)	PTC	2/22 (9.1)		
	B	0/63		
Guerra *et al.* (24)	PTC	8/50 (16.0)	18/50 (36.0)	
	B	1/30 (3.3)	4/30 (13.3)	
Overall	PTC	14/122 (11.5)	45/157 (28.7)	5/40 (12.5)
	B	2/208 (1.0)	4/234 (1.71)	0/38

PTC, papillary thyroid carcinoma; B, benign nodules; SB on RT-PCR, RT-PCR visualized by Southern blot; Q-PCR, real-time quantitative PCR.

RET/PTC rearrangement in benign and malignant thyroid diseases: a clinical standpoint
Vincenzo Marotta et al., European Journal of Endocrinology (2011) 165 499–507

mi-RNA and Thyroid FNA Diagnostics

Overview of studies that analyzed the diagnostic value of miRNAs or sets of miRNAs

Study	Material	Analyzed samples	Statistical analysis	Comparison	MicroRNAs analysed	Accuracy (%)	Sensitivity (%)	Specificity (%)	PPV (%)	NPV (%)
Nikiforova M.N. et al. 2008	Indeterminate FNAs	Derivation group: $n = 41$ Validation group: $n = 62$	LDA	Malignant vs. benign	miR-187, 221, 222, 146b, 155, 224, 197					
					If $\geqslant$ 1 miR is upregulated	95	100	94	–	–
					If $\geqslant$ 3 miRs are upregulated	98	88	100	–	–
Mazeh H. et al. 2011	FNAs of PTC and contralateral lobe, FNAs from benign tissue	PTC-group: $n = 20$ Benign group: $n = 27$	Every miRNA was analyzed seperately	PTC vs. contralateral lobe	miR-21	79	50	100	100	73
					miR-31	77	45	100	100	71
					miR-146b	91	80	100	100	87
					miR-187	79	50	100	100	73
					miR-221	98	90	100	100	93
					miR-222	96	90	100	100	93
Vriens M.R. et al. 2012	Indeterminate FNAs	78 benign, 37 malignant	Every miRNA was analyzed seperately	Malignant vs. benign		75	–	–	–	81
Rossing M et al. 2012	Snap frozen tissue	12 FTC, 12 FA, 6 NT	SVM and LOOCV	FTC vs. FA	miR-19a, 501-3p, 17, 335, 106b, 15a, 16, 374a, 542-5p, 503, 320a, 326, 330-5p, let-7i.	–	–	–	100	92
Kitano M. et al. 2012	FNAs	Derivation group: $n = 95$ Validation group: $n = 59$	Logistic regression model	Malignant vs. benign	miR-7, 126	76	100	29	36	100
Keutgen X.M. et al. 2012	indeterminate FNAs	Derivation group: $n = 29$ Validation group: $n = 72$	SVM-RBF	Malignant vs. benign	miR-222, 328, 197, 21	90	100	86	–	–
Shen R. et al. 2012	FNAs	Derivation group: $n = 60$ Validation group: $n = 68$	LDA, multivariate logistic regression classification model	Malignant vs. benign	miR-146b, 221, 187, 30d	85.3	88.9	78.3	89	78

Only articles that calculated sensitivity, specificity, accuracy, NPV, and/or PPV are included. Subanalyses are not included in this table. FA follicular adenoma; FTC follicular thyroid carcinoma; FNA Fine Needle Aspiration; PTC papillary thyroid carcinoma; LDA Linear Discriminant Analysis; SVM-RBF Support Vector Model with radial basis kernel.

- PTC (miRNA 221, 222, 146b.....?)
- FTC (miRNA 197,221...?)
- Resultate unterschiedlich!

Lodewijk L et al. „ The value of miRNA in diagnosing thyroid cancer: a systematic review Cancer Biomark. 2012;11(6):229-38.

The NEW ENGLAND JOURNAL of MEDICINE

Preoperative Diagnosis of Benign Thyroid Nodules with Indeterminate Cytology

Erik K. Alexander, M.D., Giulia C. Kennedy, Ph.D., Zubair W. Baloch, M.D., Ph.D., Edmund S. Cibas, M.D., Darya Chudova, Ph.D., James Diggans, Ph.D., Lyssa Friedman, R.N., M.P.A., Richard T. Kloos, M.D., Virginia A. LiVolsi, M.D., Susan J. Mandel, M.D., M.P.H., Stephen S. Raab, M.D., Juan Rosai, M.D., David L. Steward, M.D., P. Sean Walsh, M.P.H., Jonathan I. Wilde, Ph.D., Martha A. Zeiger, M.D., Richard B. Lanman, M.D., and Bryan R. Haugen, M.D.

-mRNA Affymetrix - Hybridisierungs - Chip

-Afirma® von Veracyte
- hohe Kosten!!

erfolgreiche mRNA Gewinnung
unklare Knoten: in 328/577
(57%)

mRNA Expressionsprofile

unklare Knoten mit Histo follow up: n=265

Performance across the Primary Data Set of Indeterminate Nodules (N=265)

GEC result	Malignant reference standard (N=85)	Benign reference standard (N=180)
Suspicious	78	87
Benign	7	93

Sensitivity, 92% (84–97); specificity, 52% (44–59); PPV, 47% (40–55); NPV, 93% (86–97); prevalence of malignant lesions, 32%

Atypia of Undetermined Significance or Follicular Lesion of Undetermined Significance (N=129, 48.7%)

GEC result	Malignant reference standard (N=31)	Benign reference standard (N=98)
Suspicious	28	46
Benign	3	52

Sensitivity, 90% (74–98); specificity, 53% (43–63); PPV, 38% (27–50); NPV, 95% (85–99); prevalence of malignant lesions, 24%

Follicular or Hürthle-Cell Neoplasm or Suspicious for Follicular Neoplasm (N=81, 30.6%)

GEC result	Malignant reference standard (N=20)	Benign reference standard (N=61)
Suspicious	18	31
Benign	2	30

Sensitivity, 90% (68–99); specificity, 49% (36–62); PPV, 37% (23–52); NPV, 94% (79–99); prevalence of malignant lesions, 25%

Suspicious for Malignancy (N=55, 20.8%)

GEC result	Malignant reference standard (N=34)	Benign reference standard (N=21)
Suspicious	32	10
Benign	2	11

Sensitivity, 94% (80–99); specificity, 52% (30–74); PPV, 76% (61–88); NPV, 85% (55–98); prevalence of malignant lesions, 62%

Performance on Cytopathologically Benign Samples (N=47)

GEC result	Malignant reference standard (N=3)	Benign reference standard (N=44)
Suspicious	3	13
Benign	0	31

Sensitivity, 100% (29–100); specificity, 70% (55–83); prevalence of malignant lesions, 6%

Performance on Cytopathologically Malignant Samples (N=55)

GEC result	Malignant reference standard (N=55)	Benign reference standard (N=0)
Suspicious	55	0
Benign	0	0

Sensitivity, 100% (93–100); prevalence of malignant lesions, 100%

Preoperative Diagnosis of Benign Thyroid Nodules with Indeterminate Cytology
Erik K. Alexander et al., N Engl J Med 2012. DOI: 10.1056/NEJMoa1203208

Summary of studies of diagnostic molecular markers on thyroid FNAB specimens with indeterminate cytology

	n*	Malignant (%)†‡	Markers	Prospective	Multicentre	Blinded	Sensitivity	NPV	Specificity	PPV
Faroux et al, 1997[28]	69	13%	A	NA	No	NA	89%	97%	58%	24%
Umbricht et al, 2004[29]	100	48%	B	No	Yes	NA	90%	87%	65%	70%
Saggiorato et al, 2005[30]	125	60%	C	No	No	Yes	100%	100%	82%	78%
Bartolazzi et al, 2008[25]	432	30%	D	Yes	Yes	Yes	78%	91%	93%	82%
Franco et al, 2009[31]	138	51%	E	Yes	No	NA	95%	92%	76%	83%
Nikiforov et al, 2009[19]	52	40%	F	Yes	Yes	Yes	71%	84%	100%	100%
Moses et al, 2010[27]	137	31%	F	Yes	No	Yes	48%	80%	94%	78%
Milas et al, 2010[24]	61	75%	G	No	No	No	59%	80%	90%	39%
Samija et al, 2011[32]	142	20%	H	Yes	No	Yes	79%	91%	53%	28%
Fadda et al, 2011[33]	119	45%	I	NA	No	NA	89%	85%	64%	71%
Nikiforov et al, 2011[20]	513	24%	J	Yes	No	No	61%	89%	98%	89%
Shen et al, 2012[34]	68	65%	K	No	No	Yes	89%	79%	79%	89%
Keutgen et al, 2012[35]	72	31%	L	Yes	Yes	Yes	100%	100%	86%	73%
Agretti et al, 2012[36]	53	28%	M	Yes	No	Yes	60%	78%	58%	39%
Rossi et al, 2012[37]	123	36%	N	Yes	No	NA	32%	73%	100%	100%
Alexander et al, 2012[26]	265	32%	O	Yes	Yes	Yes	92%	93%	52%	47%

Mingzhao Xing et al., Progress in molecular-based management of differentiated thyroid cancer, *Lancet*. 2013 March 23; 381(9871): 1058–1069.

Zusammenfassung

- Zytologie:
  - Abklärungsmethode, die
    - Kostengünstig
    - Hohe Spezifität im Vergleich zu anderen Abklärungsmethoden des SD Knotens
  - Einheitliche Klassifikation ist erstrebenswert!

Vorraussetzung: Qualität der Punktion, des Ausstrichs und der Befundung!

Molekulare Marker in der Schilddrüsenzytologie?

PTC:

- BRAF V600E
- .....

FTC:

- .....

BRAF V600E

-

ein (der) prognostischer Marker?

BRAF V600E – prognostischer Parameter

- BRAF V600E mit schlechterer Prognose und Invasivität assoziert

Namba H et al. „Clinical implication of hot spot BRAF mutation, V599E, in papillary thyroid cancers.“ J Clin Endocrinol Metab. 2003;88:4393–4397.

Elisei R, et al. „BRAF(V600E) mutation and outcome of patients with papillary thyroid carcinoma: a 15-year median follow-up study.“ J Clin Endocrinol Metab. 2008;93:3943–3949.

Basolo F et al. „Correlation between the BRAF V600E mutation and tumor invasiveness in papillary thyroid carcinomas smaller than 20 millimeters: analysis of 1060 cases.“ J Clin Endocrinol Metab. 2010;95:4197–4205.

....

- BRAF V600E nicht mit schlechterer Prognose und Invasivität assoziert

Kim TY et al. „The BRAF mutation is not associated with poor prognostic factors in Korean patients with conventional papillary thyroid microcarcinoma.“ Clin Endocrinol (Oxf). 2005 Nov;63(5):588-93.

Fugazzola L et al. „Correlation between B-RAFV600E mutation and clinico-pathologic parameters in papillary thyroid carcinoma: data from a multicentric Italian study and review of the literature.“ Endocr Relat Cancer. 2006 Jun;13(2):455-64. .

Ito Y et al. „BRAF mutation in papillary thyroid carcinoma in a Japanese population: its lack of correlation with high-risk clinicopathological features and disease-free survival of patients.“ Endocr J. 2009;56(1):89-97. Epub 2008 Oct 8.

....

Am J Surg Pathol • Volume 36, Number 6, June 2012

Immunohistochemical Detection of the BRAF V600E-mutated Protein in Papillary Thyroid Carcinoma

Oskar Koperek, MD, Christoph Kornauth, MD,* David Capper, MD,†‡ Anna Sophie Berghoff, MD,§ Reza Asari, MD,‖ Bruno Niederle, MD,‖ Andreas von Deimling, MD,†‡ Peter Birner, MD, MSc,* and Matthias Preusser, MD§*

	PTC Total n (%)	With Mutated BRAF n (%)	Without Mutated BRAF n (%)	Significant
	144 (100%)	**76 (52.8%)**	**68 (47.2%)**	***P***
Age (y)	49.9 ± 16.2 (9-85)	53.5 ± 14.6 (21-85)	45.9 ± 17 (9-80)	0.007
Sex				
Male	54 (37.5%)	33 (22.9%)	21 (14.6%)	NS
Female	90 (62.5%)	47 (23.6%)	43 (29.9%)	
Tumor diameter (mm)	16.3 ± 17 (0.5-75)	13 ± 13.7 (0.5-60)	20 ± 19.5 (1-75)	0.018
T-stage*				
pT1a	66 (45.8%)	37 (25.7%)	29 (20.1%)	NS
pT1b	18 (12.5%)	9 (6.3%)	9 (6.3%)	
pT2	16 (11.1%)	7 (4.9%)	9 (6.3%)	
pT3	42 (29.2%)	23 (16%)	19 (13.2%)	
pT4	2 (1.4%)	0 (0%)	2 (1.4%)	
Lymph node metastasis	70 (48.6%)	34 (23.6%)	36 (25%)	NS
Distant metastasis	4 (27.8%)	0 (0%)	4 (27.8%)	0.041
Multifocality	62 (43.1%)	36 (25%)	26 (18.1%)	NS
Desmoplasia				
No	13 (9%)	6 (4.2%)	7 (4.9%)	NS
Little	20 (13.9%)	10 (6.9%)	10 (6.9%)	
Moderate	69 (47.9%)	34 (23.6%)	35 (24.3%)	
Prominent	42 (29.2%)	26 (18.1%)	16 (11.1%)	
Exclusively follicular growth pattern	37 (25.7%)	12 (8.3%)	25 (17.4%)	0.004
Solid growth (at least focally)	22 (15.3%)	2 (1.4%)	20 (13.9%)	< 0.001
Oncocytic cell type and tall cell features (at least focally)	63 (43.8%)	51 (35.4%)	12 (8.3%)	< 0.001
Extrathyroidal invasion	40 (27.8%)	22 (15.3%)	18 (12.5%)	NS
Peritumoral invasion	116 (80.6%)	66 (45.8%)	50 (34.7%)	NS
Vascular invasion	39 (27.1%)	14 (9.7%)	25 (17.4%)	0.015

TABLE 2. Subtypes of PTC and V600E-Mutated BRAF Protein Expression

	PTC Total	With Mutated BRAF	Without Mutated BRAF
Papillary microcarcinoma (< 1 cm)	72/144	42	30
Classical/mixed	40/72	26	14
Exclusively follicular	27/72	12	15
Exclusively tall cell features	3/72	2	1
Exclusively oncocytic cell feature	2/72	2	0
Papillary macrocarcinoma (> 1 cm)	72/144	34	38
Classical/mixed	45/144	27	18
Follicular variant	10/72	0	10
Encapsulated	7/10	0	7
Diffuse type	2/10	0	2
Macrofollicular	1/10	0	1
Diffuse sclerosing variant	6/72	0	6
Oncocytic variant	6/72	5	1
Warthin tumor like	4/6	4	0
Tall cell variant	3/72	2	1
Solid variant	2/72	0	2

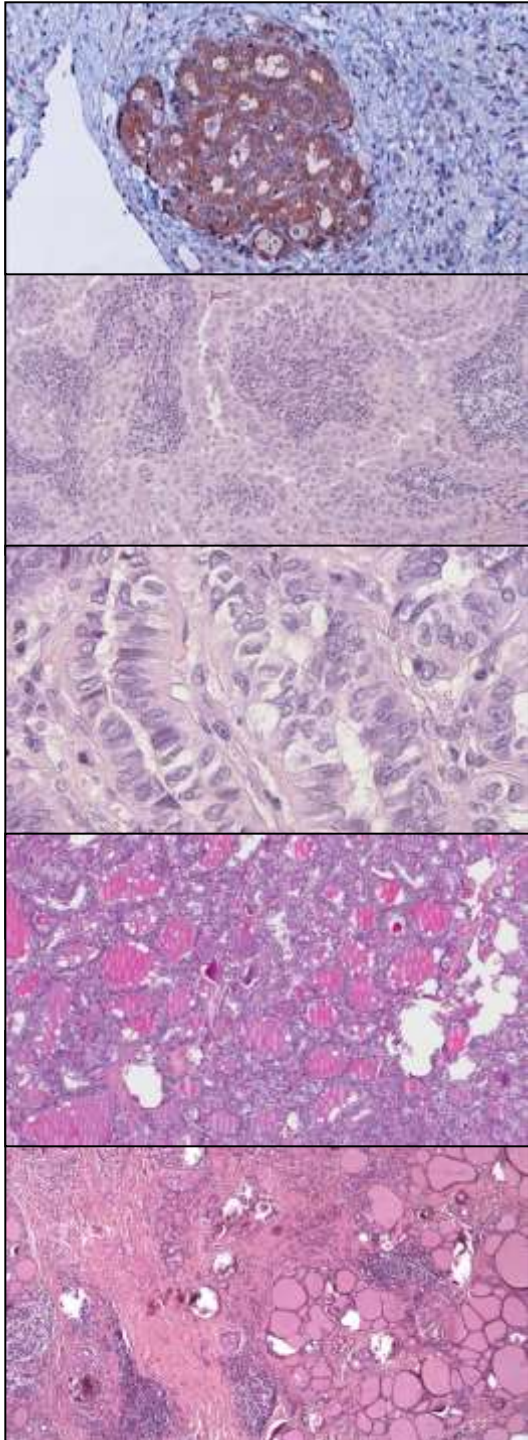

O Koperek et al., „Immunohistochemical Detection of the BRAF V600E-mutated Protein in Papillary Thyroid Carcinoma“, Am J Surg Pathol 2012;36:844–850

JAMA, April 10, 2013—Vol 309, No. 14 **1493**

Association Between *BRAF* V600E Mutation and Mortality in Patients With Papillary Thyroid Cancer

Xing M, Alzahrani AS, Carson KA, Viola D, Elisei R, Bendlova B, Yip L, Mian C, Vianello F, Tuttle RM, Robenshtok E, Fagin JA, Puxeddu E, Fugazzola L, Czarniecka A, Jarzab B, O'Neill CJ, Sywak MS, Lam AK, Riesco-Eizaguirre G, Santisteban P, Nakayama H, Tufano RP, Pai SI, Zeiger MA, Westra WH, Clark DP, Clifton-Bligh R, Sidransky D, Ladenson PW, Sykorova V.

Figure 1. Kaplan-Meier Survival Curves of PTC-Specific Survival by *BRAF* V600E Mutation Status



No. at risk

BRAF V600E positive	845	530	309	197	147	95	65
BRAF V600E negative	1004	640	393	243	177	127	87

No. at risk

BRAF V600E positive	659	411	246	162	121	79	56
BRAF V600E negative	574	375	240	143	101	80	61

Comparison of patient survival, represented by log-rank *P* values in each panel, was performed between *BRAF* V600E–negative and *BRAF* V600E–positive groups for all patients and for patients with conventional papillary thyroid cancer (PTC). Follow-up time is truncated at 12 years.

- 845 BRAF pos. Fälle bei 1849 Patienten (45.7%)
- nur 56 PTC assozierte Todesfälle (45 BRAF+, 11 BRAF-) bei 1849 Patienten
- davon im Stadium I und II nur 3 Todesfälle (2xBRAF+, 1x BRAF-) bei 1311 Patienten!

DANKE!